

Review

Cytomegalovirus pneumonia in patients with inflammatory bowel disease: a systematic review

Antonio Cascio^{a,b,*}, Chiara Iaria^{b,c}, Paolo Ruggeri^d, Walter Fries^e

^a Tropical and Parasitological Diseases Unit, Department of Human Pathology, Policlinico "G. Martino", Via Consolare Valeria n. 1, 98125 Messina, Italy

^b AILMI (Italian Association for the Control of Infectious Diseases), University of Messina, Messina, Italy

^c Infectious Diseases Unit - Azienda Ospedaliera Piemonte-Papardo, Messina, Italy

^d Department of Clinical and Experimental Medicine and Pharmacology, University of Messina, Messina, Italy

^e Department of Internal Medicine, University of Messina, Messina, Italy

ARTICLE INFO

Article history:

Received 19 October 2011

Received in revised form 6 March 2012

Accepted 11 March 2012

Corresponding Editor: William Cameron, Ottawa, Canada

Keywords:

Crohn's diseases

Cytomegalovirus

Hemophagocytic lymphohistiocytosis

Inflammatory bowel diseases

Pneumonia

Ulcerative colitis

SUMMARY

Background: Inflammatory bowel disease (IBD) patients are at increased risk of cytomegalovirus (CMV) reactivation, and although CMV pneumonia may be a fatal disease in IBD patients, little information is available on this issue. The objectives of this study were to identify risk factors for the development of CMV pneumonia in IBD patients and to find useful information to better manage this potentially fatal complication.

Methods: A computerized search without language restrictions was conducted using PubMed and SCOPUS. An article was considered eligible for inclusion in the systematic review if it reported detailed data on patients with IBD presenting with pneumonia due to CMV.

Results: Overall, 12 articles describing the history of 13 patients, published between the years 1996 and 2011, were finally considered. All patients were adults with a mean age of 33 years, and 11/13 were females. Fever and dyspnea were the most frequent symptoms. The most frequent radiological signs were bilateral pulmonary infiltrates. Six cases were complicated by hemophagocytic lymphohistiocytosis. Eight of the 13 were transferred to intensive care units and four of them died.

Conclusions: CMV pneumonia should always be suspected in IBD patients who present with fever and tachypnea, especially if the latter is worsening and/or is associated with dyspnea. Treatment must be early and specific.

© 2012 International Society for Infectious Diseases. Published by Elsevier Ltd. All rights reserved.

1. Introduction

As with all herpes viruses, cytomegalovirus (CMV) establishes a latent infection in the host following recovery from an acute infection. Activation from this latent state can occur with immunosuppression, other illness, or the use of chemotherapeutic agents. Clinical CMV disease can result from either a primary or a secondary infection; in a primary infection, the virus usually replicates to a higher level and the disease is more severe.

The role of CMV in inflammatory bowel disease (IBD) remains controversial.¹ Initial studies reported CMV inclusion bodies in colectomy specimens from patients with fulminant or steroid-refractory ulcerative colitis (UC).² Other studies have questioned the pathogenicity of CMV in active IBD by demonstrating a lack of correlation of CMV and the clinical severity of IBD.³ However, despite arguments on the non-pathogenicity of CMV reactivation, the overall existing literature indicates that IBD patients are at

increased risk of CMV reactivation, and that the failure to appropriately diagnose and treat these patients promptly leads to significant morbidity and mortality. This increased risk is likely multifactorial, due in part to both iatrogenic immunosuppression and underlying factors related to severe inflammation, possible malnutrition, and inherent immunogenicity.⁴ Although CMV pneumonia may be a fatal disease in IBD patients,⁵ very little information is available in the international literature on this issue and CMV pneumonia was not mentioned in two recent reviews on possible pulmonary complications during IBD.^{6,7}

The objective of this review was to focus attention on this potentially fatal disease, which we believe to be under-recognized, at least in its initial manifestation, and to try to recognize those characteristics of IBD patients that could be associated with CMV pneumonia.

2. Methods

A computerized search without language restrictions was conducted using PubMed and SCOPUS. The search was performed

* Corresponding author. Tel.: +39 090 2213680; fax: +39 090 692610.
E-mail address: acascio@unime.it (A. Cascio).

combining the terms (CMV OR cytomegalovirus OR ganciclovir) AND (IBD OR Crohn OR ulcerative colitis OR inflammatory bowel disease), without limits. Furthermore, all references listed were hand-searched for other relevant articles. An article was considered eligible for inclusion in the systematic review if it reported detailed data on patients with IBD who presented with pneumonia due to CMV. CMV pneumonia was diagnosed in the presence of at least: (1) positive radiology or autopsy findings of pneumonia, and (2) pp65 antigenemia and/or CMV DNA in blood and/or positive anti-CMV IgM and IgG titers, and (3) absence of other cause of pneumonia. In the presence of another cause of pneumonia, the detection of CMV inclusion bodies/immunohistochemical stain/culture in biopsies/autopsy, or PCR on bronchoalveolar lavage (BAL) fluid was considered necessary. The Preferred Reporting Items for Systematic Review and Meta-Analysis (PRISMA) guidelines were followed.⁸

3. Results

The PubMed search identified 387 publications, a scrupulous analysis of which resulted in 13 eligible articles.^{5,9–20} One other article (not present in PubMed) was found through the SCOPUS search.²¹ Overall, 14 articles describing the history of 16 patients, published between the years 1996 and 2011, were further evaluated. A paper reporting two cases of CMV pneumonia but lacking detailed information about the patients was excluded.¹⁹ A

case of UC with detectable circulating CMV DNA, in whom respiratory symptoms were present but chest X-ray (performed only once) was negative, was also excluded.²⁰ A flow-diagram summarizing the literature research approach is shown in Figure 1.

Data regarding the clinical characteristics, therapy, and outcome of the 13 patients are given in Table 1. All patients were adults with a mean age of 33 years (median age 28 years, range 18–77 years), and 11/13 were females. Ten suffered from Crohn's disease (CD) and three from UC. The mean length of the IBD before the appearance of respiratory symptoms was 8 years (median duration 4.5 years, range 7 months–30 years). Five CD patients came from Europe, four from North America, and one from Australia.

Nine patients were under treatment with azathioprine (alone in four cases and associated with 5-aminosalicylic acid, steroids, and/or infliximab in the others), two patients were under treatment with 6-mercaptopurine (in one case associated with steroids, cyclosporine A, and 5-aminosalicylic acid), one patient was under treatment with steroids and leukocytapheresis, and one was on steroids plus cyclosporine A and 5-aminosalicylic acid. The mean length of treatment with azathioprine before the appearance of respiratory symptoms was 30 months and the median was 19 months.

Signs and symptoms were reported in all but two cases.^{13,16} Fever was present in 11 cases, dyspnea or reduced oxygen saturation (SaO₂) was reported in eight cases, cough in five cases,

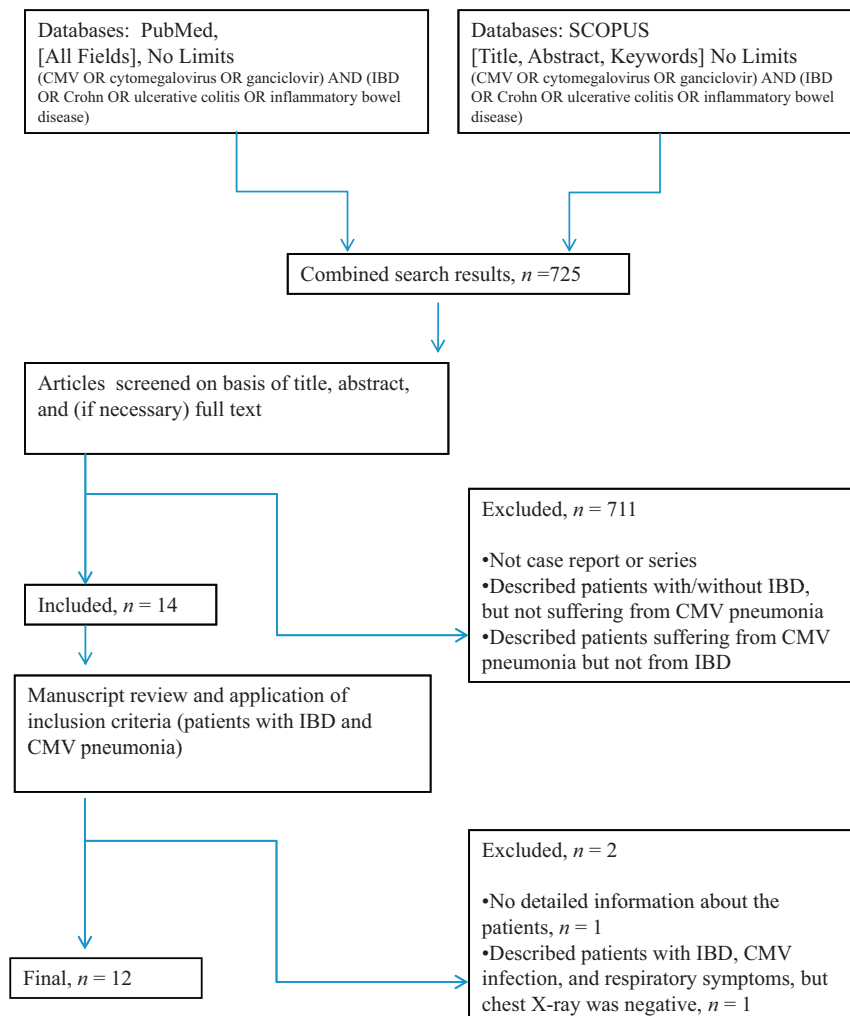


Figure 1. Flow of information through the different phases of the review.

Table 1
Clinical characteristics, therapy, and outcome of 13 IBD patients with CMV pneumonia

Author, year [Ref.] (note)	Sex/age/nation	IBD (duration)	IBD therapy (length of treatment)	Hematological findings	Symptoms, PE, CMV diagnosis, and treatment	HLH	Radiological findings	Outcome
Sijpkens, 1996 [9]	F/20/the Netherlands	CD (3 years)	Steroids and 5-ASA (3 years); AZA (19 months)	Pancytopenia	15-day history of fever, headache, mild dyspnea, nonproductive cough, weakness; then severe dyspnea PE: fever (41.2 °C), normal breath sounds Positive anti-CMV IgM and IgG titers; positive pp65 antigenemia AZA stopped, steroids continued; ganciclovir for 17 days	Yes	Chest X-ray: bilateral interstitial infiltrates	Cured; follow-up not reported
Papadakis, 2001 [10]	M/51/USA	CD (23 years)	CSA, 6-MP, steroids, 5-ASA (NR)	Lymphopenia, neutropenia	Fever (39 °C), dyspnea, diarrhea PE: NR CMV inclusion in BAL, positive CMV culture from bronchoscopic biopsies, CMV IgM, <i>Pneumocystis carinii</i> organisms and <i>Nocardia</i> species 6-MP stopped; ganciclovir, trimethoprim/sulfamethoxazole, other antibiotics, and G-CSF	NR	NR	Died on day 45 of hospitalization; gastrointestinal bleeding, ARDS, and multisystem failure
Hookey, 2003 [11]	F/19/Canada	Quiescent CD (9 years)	6-MP (18 months)	Leukopenia (WBC $2.6 \times 10^9/l$)	1-month history of fever, chills, poor appetite and a progressively worse nonproductive cough, dyspnea PE: fever (39.4 °C), normal breath sounds at admission, fine crackles in both lung fields on day 2 CMV inclusion in transbronchial biopsy Intubated; 6-MP stopped; ganciclovir, immunoglobulin, and steroids	NR	Normal chest X-ray at beginning of diseases and interstitial pattern 2 days after	Cured, 6-MP not restarted; follow-up 6 months
Kak, 2004 [21] (not PubMed)	F/19/USA	CD (3 years)	AZA (NR), 5-ASA (NR); infliximab and steroids (3 weeks)	Leukopenia (WBC $0.8 \times 10^9/l$)	2-day history of fever (up to 40 °C) and bilateral sharp chest pains exacerbated by deep breaths PE: normal breath sounds, increasing shortness of breath, and hypoxemia; ICU Positive CMV IgM; CMV inclusion in BAL Stopping AZA not reported; high-dose ganciclovir	NR	Chest X-ray and CT: bilateral infiltrates	Mechanical ventilation for nearly 2 weeks; cured; follow-up not reported
Alderson, 2005 [12]	F/55/USA	CD (30 years)	Steroids (3 months), AZA (4 weeks), infliximab (10 days)	NR	Low-grade fever, shortness of breath PE: NR Postmortem lung tissue cultures were positive for <i>Aspergillus fumigatus</i> ; CMV pneumonia confirmed by immunohistochemical stains and culture AZA stopped	NR	Chest X-ray: diffuse bilateral infiltrates (mixed but predominantly alveolar)	Died
Sato, 2007 [5]	F/77/Japan	UC (7 months)	Steroids (6 months), leukocytapheresis (10 weeks)	Severe anemia, thrombocytopenia	High fever, dyspnea PE: NR CMV-pp65 antigenemia positive Autopsy Ganciclovir	NR	Ground-glass appearance of both lungs	ARDS, bilateral pneumothorax; died
Piton, 2008 [13]	F/18/France	UC (2 years)	5-ASA (2 years), steroids (15 days), cyclosporine (3 days)	NR	Symptoms and PE: NR Positive anti-CMV IgM and IgG titers; positive pp65 antigenemia; blood CMV DNA: 150,000 gEq/ml; CMV inclusion in BAL Ganciclovir for 28 days, steroids	NR	Chest X-ray: diffuse bilateral infiltrates	Relapse of UC and CMV infection 2 months later, new course of ganciclovir; cured; follow-up not reported

Table 1 (Continued)

Author, year [Ref.] (note)	Sex/age/nation	IBD (duration)	IBD therapy (length of treatment)	Hematological findings	Symptoms, PE, CMV diagnosis, and treatment	HLH	Radiological findings	Outcome
De Boer, 2008 [14]	F/26/the Netherlands	CD (16 years)	AZA and 5-ASA (10 years), steroids (NR)	Pancytopenia	Fever, myalgia, coughing, and diarrhea PE: NR Positive anti-CMV IgM and IgG titers AZA and 5-ASA stopped, no antivirals	NR	Chest X-ray: normal; chest CT: bilateral pneumonia	Cured; follow-up 10 months
Wolschke, 2010 [15]	F/28/Germany	CD (11 years)	AZA (2 years)	Pancytopenia (WBC $2.0 \times 10^9/l$, Hb 7.4 g/dl, PLT $99 \times 10^9/l$)	High fever, dyspnea, cough PE: bi-basal crepitations, SaO ₂ 86%, ICU, intubated BAL CMV DNA: 300 gEq/ml; blood CMV DNA: 7000 gEq/ml Stopping AZA not reported; ganciclovir + prednisone + etoposide + CSA	Yes	Chest X-ray: bilateral pleural effusion, infiltrates on the right lung	Cured; follow-up not reported
Nguyen, 2011 [16]	F/38/France	CD (NR)	AZA (2 years)	Cytopenia	Symptoms, PE, and diagnosis: NR AZA stopped; steroids, ganciclovir/valganciclovir, foscarnet, polyvalent immunoglobulins	Yes	Bilateral involvement	Died
Lo Presti, 2011 [17]	F/32/Italy	Quiescent CD (6 years)	AZA (8 months)	Pancytopenia (WBC $1.26 \times 10^9/l$, Hb 8.1 g/dl, PLT $53 \times 10^9/l$)	3-day history of fever and weakness PE: temp. 39.0 °C, tachypnea, normal breath sounds, SaO ₂ 82%, worsening dyspnea, ICU Blood CMV DNA: 2670 gEq/100,000 cells AZA stopped; ganciclovir/valganciclovir	Yes	Chest X-ray: diffuse bilateral infiltrates	Cured; follow-up 12 months
van Langenberg, 2011 [18] (2 cases)	F/32/Australia	UC (10 years)	AZA, 5-ASA (2 years)	Pancytopenia	7-day history of fever, lethargy, myalgia, and headache PE: productive cough, right basal crepitations, SaO ₂ 86%, ICU, intubated CMV IgM was positive; blood CMV DNA: 294,000 gEq/ml, BAL CMV DNA positive AZA stopped; ganciclovir + foscarnet + steroids	Yes	Chest X-ray: consolidation with small bilateral pleural effusions; CT: bilateral mid-lower zone alveolar infiltrates, early consolidation	Cured
	M/22/Australia	CD (3 years)	AZA (1 year)	Pancytopenia	2-week history of fatigue, malaise, fevers and sore throat PE: temp. 39.0 °C, tachycardia, bi-basal crepitations CMV serology, positive IgM but negative IgG antibodies; CMV PCR of serum and BAL were positive AZA stopped; ganciclovir	Yes	Chest X-ray: NR; CT scan: bilateral, patchy alveolar opacification	Cured; follow-up 16 months

5-ASA, 5-aminosalicylic acid; ARDS, acute respiratory distress syndrome; AZA, azathioprine; BAL, bronchoalveolar lavage; CD, Crohn's diseases; CMV, cytomegalovirus; CSA, cyclosporine; CT, computed tomography; F, female; G-CSF, granulocyte colony stimulating factor; gEq, genome equivalents; Hb, hemoglobin; HLH, hemophagocytic lymphohistiocytosis; IBD, inflammatory bowel disease; ICU, intensive care unit; M, male; 6-MP, 6-mercaptopurine; PE, physical examination; NR, not reported; PLT, platelets; UC, ulcerative colitis; WBC, white blood cell count.

and chest pain in one case. Worsening dyspnea necessitating mechanical ventilation was reported in eight cases. Normal breath sounds at lung auscultation on patient admission were found in four cases, basal crepitations in three cases, and in the remaining cases auscultation results were not reported.

Radiological findings were described in all but one case.¹⁰ Diffuse bilateral infiltrates were described in nine cases. A mixed but predominantly alveolar pattern was described in a case in whom an *Aspergillus fumigatus* infection was also documented.¹² Alveolar infiltrates were described in two cases in whom no other cause of pneumonia was diagnosed. Chest X-ray performed at the beginning of the disease failed to identify signs of pneumonia in two cases.^{11,14}

Methods used to diagnose CMV pneumonia were reported in all but one case.¹⁶ Diagnosis was made by the detection of CMV inclusion bodies/immunohistochemical stain/culture in biopsies/autopsy in five cases,^{10–13,21} by polymerase chain reaction (PCR) on bronchoalveolar lavage (BAL) fluid in three cases,^{15,18} by PCR on peripheral blood in one case,¹⁷ by serology accompanied by a positive pp65 antigenemia in one case,⁹ by a positive pp65 antigenemia later confirmed by autopsy in one case,⁵ and only by serology in one case.¹⁴ Six cases were complicated by hemophagocytic lymphohistiocytosis (HLH).^{9,15–18} In one other case with severe anemia and thrombocytopenia who died due to acute respiratory distress syndrome (ARDS), HLH was apparently not diagnosed.⁵

Concomitant infections, one with *Pneumocystis carinii* (*jiroveci*) and *Nocardia* species and another with *Aspergillus fumigatus*, were diagnosed in two fatal cases.^{10,12} In all the other cases another possible diagnosis of interstitial pneumonia was ruled out.

Azathioprine and 6-mercaptopurine were stopped in 7/9 and 2/2 cases, respectively. Ganciclovir was used in 11 cases; in one case no antiviral agent was used because the diagnosis was made post mortem¹² and in one case the pneumonia resolved without antiviral treatment after the withdrawal of azathioprine.¹⁴ Ganciclovir was used alone or associated with foscarnet and/or intravenous (IV) immunoglobulins (three cases). Oral valganciclovir was used after IV ganciclovir in two cases. Eight of the 13 cases were transferred to an intensive care unit and four of them died.

4. Discussion

Analysis of the retrieved cases showed many interesting points, including the gender distribution, IBD subtype, high fatality rates, initial difficulties in diagnosis, possible complication with HLH, and, finally, the best therapeutic approach.

The gender distribution in IBD has been investigated thoroughly in recent decades. Population-based studies have shown no predominance of any sex in UC, whereas data from CD point to slight differences, with female/male ratios that range from 1.1:1 to 2.2:1.²² These data do not explain the female/male ratio in our series of 5.5:1. Several hypotheses may be considered to explain this finding. First, women are more susceptible to CMV pneumonia; second, women develop more severe forms that result in a diagnosis; and third, younger women (the mean age in our series was 33 years) may be more exposed to CMV through their children. However no data on maternal status were reported in the retrieved reports.

Concerning the disease subtype, CD was the underlying disease in 77% of the cases. A possible explanation for this is that immunosuppression is more common in CD compared to UC.

Eleven out of 13 (85%) patients retrieved in our review were on treatment with thiopurines (nine with azathioprine and two with 6-mercaptopurine) when they developed CMV pneumonia. Thiopurines can be considered a standard therapy for IBD

according to the most recent guidelines.^{23–26} However, it is becoming apparent that compared to other immunomodulators/biologicals typically used, thiopurines carry a disproportionately higher risk of the reactivation of viral infections, beyond CMV, including activating warts (human papillomavirus) with possible resulting cervical dysplasia/cancer,²⁷ and Epstein–Barr virus leading to an increased risk of related lymphomas.²⁸ Thus, for fear of another future CMV reactivation, it is possible that switching these patients from a thiopurine to an alternative treatment after recovery from CMV pneumonia may be safer than resuming the thiopurine.

CMV pneumonia is one of the most important opportunistic infections in the immunocompromised host. Clinically, CMV pneumonia usually shows an interstitial pattern, but nodules may also be present on chest radiographic films. It is usually rapid in onset, with respiratory symptoms of less than 2 weeks in duration. Fever, nonproductive cough, and dyspnea that progresses to hypoxia are common in severe cases. Hypoxia frequently necessitates assisted mechanical ventilation.²⁹ Since there is no pathognomonic clinical finding in CMV pneumonia, BAL examination or transbronchial biopsy are generally required for diagnosis. However, no consensus exists regarding the specific criteria for establishing this diagnosis and to rule out potentially coexisting opportunistic infections.³⁰ Other causes of interstitial pneumonia reported in IBD patients are: *P. jiroveci*, miliary tuberculosis, varicella pneumonia, nocardiosis, histoplasmosis, influenza, adenovirus infection, Q fever, and legionellosis.^{31–41} Furthermore, in cases of atypical pneumonia without a proven opportunistic infection, azathioprine-associated interstitial pneumonitis may be considered, which heals after withdrawal of the drug.^{42,43} The chest X-ray was initially negative in two of the patients in this study. This finding is not unusual in CMV pneumonia. A recent paper has described a case in whom a chest CT scan was also initially unremarkable.⁴⁴

Finally, HLH was contextually present in six cases and was probably triggered by the CMV infection. HLH is a potentially fatal hyperinflammatory syndrome characterized by histiocyte proliferation and hemophagocytosis. HLH may be inherited (primary, familial), which occurs generally in infants, or may be secondary to severe infection, malignancy, or a rheumatologic condition, occurring at any age.⁴⁵ HLH may cause systemic inflammatory response syndrome, ARDS, and septic shock.⁴⁶ Without treatment, familial HLH is often rapidly fatal, and the reported mortality for secondary HLH can exceed 50%. In the presence of cytopenia (affecting two or more lineages in the peripheral blood) a diagnosis of HLH should be suspected. However, the first assumption about a patient with pancytopenia on azathioprine therapy is that the pancytopenia is drug-related. Bone marrow suppression can occur after a delay, but is reversible upon discontinuation of the drug. The absence of severe bone marrow hypocellularity is evidence against a direct role of azathioprine in the pancytopenia.⁹

From the analysis of our data we cannot extrapolate an indication of the best treatment for CMV pneumonia. For patients with CMV esophagitis, colitis, or rectal ulcers, improvement in clinical symptoms is usually noted during the first week of therapy with valganciclovir, ganciclovir, or foscarnet. In bone marrow transplant recipients with CMV pneumonia, IV ganciclovir is usually given concurrently with immune serum globulin or hyperimmune globulin. However, there are no convincing data to show that immune or hyperimmune globulin enhances efficacy. As a result of this experience, immune serum globulin is often administered to patients with HIV infection and suspected CMV pneumonia as an adjunct to ganciclovir or foscarnet.³⁰ The duration of therapy is usually about 2 weeks, but this may be extended to 3 weeks or longer in patients with severe disease or a primary infection. In patients with CMV disease and viremia,

therapy should be continued until resolution of CMV viremia, because the risk of relapse is lower in patients who do not have detectable CMV DNA after ganciclovir therapy.

This study has many limitations because the literature data on this topic are few and heterogeneous. Epidemiological data on the incidence of CMV pneumonia in patients with IBD cannot be extrapolated. A prospective, structured, multicenter study would be necessary to determine the real epidemiological scenario of this potentially fatal complication.

In conclusion, CMV pneumonia should be suspected in IBD patients who present fever and tachypnea, especially if the latter is worsening and/or is associated with dyspnea. Chest X-ray should be repeated if negative and CT may be advisable. CMV serology and PCR in the blood should be performed, as well as a search for CMV in BAL. While awaiting the virological results, we recommend the prompt initiation of antiviral therapy. In the presence of cytopenia (affecting two or more lineages in the peripheral blood) a diagnosis of HLH should be suspected.

Conflict of interest: None of the authors have any conflicts of interest associated with the work presented in this manuscript.

References

- Kim JJ, Simpson N, Klipfel N, Debose R, Barr N, Laine L. Cytomegalovirus infection in patients with active inflammatory bowel disease. *Dig Dis Sci* 2010;**55**:1059–65.
- Kuwabara A, Okamoto H, Suda T, Ajioka Y, Hatakeyama K. Clinicopathologic characteristics of clinically relevant cytomegalovirus infection in inflammatory bowel disease. *J Gastroenterol* 2007;**42**:823–9.
- Matsuoka K, Iwao Y, Mori T, Sakuraba A, Yajima T, Hisamatsu T, et al. Cytomegalovirus is frequently reactivated and disappears without antiviral agents in ulcerative colitis patients. *Am J Gastroenterol* 2007;**102**:331–7.
- Nguyen M, Bradford K, Zhang X, Shih DQ. Cytomegalovirus reactivation in ulcerative colitis patients. *Ulcers* 2011;2011. pii: 282507.
- Sato S, Kobayashi H, Saito R, Sasajima T, Orikasa H, Watanabe H, et al. A case of steroid-refractory ulcerative colitis complicated with cytomegalovirus pneumonia. *Fukushima J Med Sci* 2007;**53**:27–32.
- Basseri B, Enayati P, Marchevsky A, Papadakis KA. Pulmonary manifestations of inflammatory bowel disease: case presentations and review. *J Crohns Colitis* 2010;**4**:390–7.
- Casella G, Villanacci V, Di Bella C, Antonelli E, Baldini V, Bassotti G. Pulmonary diseases associated with inflammatory bowel diseases. *J Crohns Colitis* 2010;**4**:384–9.
- Liberati A, Altman DG, Tetzlaff J, Mulrow C, Gotzsche PC, Ioannidis JP, et al. The PRISMA statement for reporting systematic reviews and meta-analyses of studies that evaluate health care interventions: explanation and elaboration. *PLoS Med* 2009;**6**:e1000100.
- Sijpkens YW, Allaart CF, Thompson J, van't Wout J, Kluin PM, den Ottolander GJ, et al. Fever and progressive pancytopenia in a 20-year-old woman with Crohn's disease. *Ann Hematol* 1996;**72**:286–90.
- Papadakis KA, Tung JK, Binder SW, Kam LY, Abreu MT, Targan SR, et al. Outcome of cytomegalovirus infections in patients with inflammatory bowel disease. *Am J Gastroenterol* 2001;**96**:2137–42.
- Hookey LC, Depew W, Boag A, Vanner S. 6-mercaptopurine and inflammatory bowel disease: hidden ground for the cytomegalovirus. *Can J Gastroenterol* 2003;**17**:319–22.
- Alderson JW, Van Dinter Jr TG, Opatowsky MJ, Burton EC. Disseminated aspergillosis following infliximab therapy in an immunosuppressed patient with Crohn's disease and chronic hepatitis C: a case study and review of the literature. *MedGenMed* 2005;**7**:7.
- Piton G, Dupont-Gossart AC, Weber A, Herbein G, Viennet G, Manton G, et al. Severe systemic cytomegalovirus infections in patients with steroid-refractory ulcerative colitis treated by an oral microemulsion form of cyclosporine: report of two cases. *Gastroenterol Clin Biol* 2008;**32**:460–4.
- de Boer NK, van Bodegraven AA, de Graaf P, van der Hulst RW, Zoetekouw L, van Kuilenburg AB. Paradoxical elevated thiopurine S-methyltransferase activity after pancytopenia during azathioprine therapy: potential influence of red blood cell age. *Ther Drug Monit* 2008;**30**:390–3.
- Wolschke C, Fiedler W, Habermann RC, Janka-Schaub GE, Kluge S. [28-year old female patient with respiratory insufficiency, elevated liver enzymes, pancytopenia and fever]. *Internist (Berl)* 2010;**51**:1434–8.
- N'Guyen Y, Baumard S, Salmon JH, Lemoine L, Leveque N, Servettaz A, et al. Cytomegalovirus associated hemophagocytic lymphohistiocytosis in patients suffering from Crohn's disease treated by azathioprine: a series of four cases. *Inflamm Bowel Dis* 2011;**17**:E116–8.
- Lo Presti MA, Costantino G, Della Torre A, Belvedere A, Cascio A, Fries W. Severe CMV-related pneumonia complicated by the hemophagocytic lymphohistiocytosis (HLH) syndrome in quiescent Crohn's colitis: harmful cure? *Inflamm Bowel Dis* 2011;**17**:145–6.
- van Langenberg DR, Morrison G, Foley A, Buttigieg RJ, Gibson PR. Cytomegalovirus disease, haemophagocytic syndrome, immunosuppression in patients with IBD: 'a cocktail best avoided, not stirred'. *J Crohns Colitis* 2011;**5**:469–72.
- Cottone M, Pietrosi G, Martorana G, Casa A, Pecoraro G, Oliva L, et al. Prevalence of cytomegalovirus infection in severe refractory ulcerative and Crohn's colitis. *Am J Gastroenterol* 2001;**96**:773–5.
- Petrache A, Moller MB, Frederiksen H. [Hemophagocytosis associated with cytomegalovirus infection and azathioprine treatment for inflammatory bowel disease]. *Ugeskr Laeger* 2010;**172**:52–3.
- Kak V, Havlichek D. Fulminant cytomegaloviral pneumonia after infliximab in a patient with Crohn disease. *Infect Dis Clin Pract* 2004;**12**:311–3.
- Brant SR, Nguyen GC. Is there a gender difference in the prevalence of Crohn's disease or ulcerative colitis? *Inflamm Bowel Dis* 2008;**14**(Suppl 2):S2–3.
- Mowat C, Cole A, Windsor A, Ahmad T, Arnott I, Driscoll R, et al. Guidelines for the management of inflammatory bowel disease in adults. *Gut* 2011;**60**:571–607.
- Lichtenstein GR, Hanauer SB, Sandborn WJ. Management of Crohn's disease in adults. *Am J Gastroenterol* 2009;**104**:465–83. quiz 4, 84.
- Dignass A, Van Assche G, Lindsay JO, Lemann M, Soderholm J, Colombel JF, et al. The second European evidence-based consensus on the diagnosis and management of Crohn's disease: current management. *J Crohns Colitis* 2011;**4**:28–62.
- Travis SP, Stange EF, Lemann M, Oresland T, Bemelman WA, Chowers Y, et al. European evidence-based consensus on the management of ulcerative colitis: current management. *J Crohns Colitis* 2008;**2**:24–62.
- Seksik P, Cosnes J, Sokol H, Nion-Larmurier I, Gendre JP, Beaugerie L. Incidence of benign upper respiratory tract infections, HSV and HPV cutaneous infections in inflammatory bowel disease patients treated with azathioprine. *Aliment Pharmacol Ther* 2009;**29**:1106–13.
- Beaugerie L, Brousse N, Bouvier AM, Colombel JF, Lemann M, Cosnes J, et al. Lymphoproliferative disorders in patients receiving thiopurines for inflammatory bowel disease: a prospective observational cohort study. *Lancet* 2009;**374**:1617–25.
- Meyers JD, Flournoy N, Thomas ED. Risk factors for cytomegalovirus infection after human marrow transplantation. *J Infect Dis* 1986;**153**:478–88.
- Uberti-Foppa C, Lillo F, Terreni MR, Puglisi A, Guffanti M, Gianotti N, et al. Cytomegalovirus pneumonia in AIDS patients: value of cytomegalovirus culture from BAL fluid and correlation with lung disease. *Chest* 1998;**113**:919–23.
- Itaba S, Iwasa T, Sadamoto Y, Nasu T, Misawa T, Inoue K, et al. Pneumocystis pneumonia during combined therapy of infliximab, corticosteroid, and azathioprine in a patient with Crohn's disease. *Dig Dis Sci* 2007;**52**:1438–41.
- Stas P, D'Hoore A, Van Assche G, Geboes K, Steenkiste E, Penninckx F, et al. Miliary tuberculosis following infliximab therapy for Crohn disease: a case report and review of the literature. *Acta Gastroenterol Belg* 2006;**69**:217–20.
- Lawrance IC, Radford-Smith GL, Bampton PA, Andrews JM, Tan PK, Croft A, et al. Serious infections in patients with inflammatory bowel disease receiving antitumor necrosis factor- α therapy: an Australian and New Zealand experience. *J Gastroenterol Hepatol* 2010;**25**:1732–8.
- Monaghan TM, Norton B. Varicella pneumonia in an immunocompromised inflammatory bowel disease patient. *Inflamm Bowel Dis* 2010;**16**:364–5.
- Lemyze M, Tavernier JY, Chevalon B, Lamblin C. [Severe varicella zoster pneumonia during the course of treatment with azathioprine for Crohn's disease]. *Rev Mal Respir* 2003;**20**:773–6.
- Stratakos G, Kalomenidis I, Papas V, Malagari K, Kollintza A, Roussos C, et al. Cough and fever in a female with Crohn's disease receiving infliximab. *Eur Respir J* 2005;**26**:354–7.
- Dotson JL, Crandall W, Mousa H, Honegger JR, Denson L, Samson C, et al. Presentation and outcome of histoplasmosis in pediatric inflammatory bowel disease patients treated with antitumor necrosis factor alpha therapy: a case series. *Inflamm Bowel Dis* 2011;**17**:56–61.
- Rahier JF, Papay P, Salleron J, Sebastian S, Ellul P, Teich N, et al. Influenza A (H1N1)v infection in patients with inflammatory bowel disease: a case series. *Aliment Pharmacol Ther* 2011;**33**:499–500.
- Ahmad NM, Ahmad KM, Younus F. Severe adenovirus pneumonia (AVP) following infliximab infusion for the treatment of Crohn's disease. *J Infect* 2007;**54**:e29–32.
- Nausheen S, Cunha BA. Q fever community-acquired pneumonia in a patient with Crohn's disease on immunosuppressive therapy. *Heart Lung* 2007;**36**:300–3.
- Epping G, van der Valk PD, Hendrix R. *Legionella pneumophila* pneumonia in a pregnant woman treated with anti-TNF- α antibodies for Crohn's disease: a case report. *J Crohns Colitis* 2010;**4**:687–9.
- Ananthakrishnan AN, Attala T, Otterson MF, Lipchik RJ, Massey BT, Komorowski RA, et al. Severe pulmonary toxicity after azathioprine/6-mercaptopurine initiation for the treatment of inflammatory bowel disease. *J Clin Gastroenterol* 2007;**41**:682–8.
- Nagy F, Molnar T, Makula E, Kiss I, Milassin P, Zollei E, et al. A case of interstitial pneumonitis in a patient with ulcerative colitis treated with azathioprine. *World J Gastroenterol* 2007;**13**:316–9.
- van Duin D, Miranda C, Husni E. Cytomegalovirus viremia, pneumonitis, and tocilizumab therapy. *Emerg Infect Dis* 2011;**17**:754–6.
- Gupta S, Weitzman S. Primary and secondary hemophagocytic lymphohistiocytosis: clinical features, pathogenesis and therapy. *Expert Rev Clin Immunol* 2010;**6**:137–54.
- Raschke RA, Garcia-Orr R. Hemophagocytic lymphohistiocytosis: a potentially underrecognized association with systemic inflammatory response syndrome, severe sepsis, and septic shock in adults. *Chest* 2011;**140**:933–8.