



Contents lists available at ScienceDirect

International Journal of Infectious Diseases

journal homepage: [www.elsevier.com/locate/ijid](http://www.elsevier.com/locate/ijid)

## Case Report

## Zika, dengue, and chikungunya co-infection in a pregnant woman from Colombia



Wilmer E. Villamil-Gómez<sup>a,b,1</sup>, Alfonso J. Rodríguez-Morales<sup>a,c,1</sup>,  
Ana María Uribe-García<sup>d</sup>, Edgardo González-Arismendy<sup>d</sup>, Jaime E. Castellanos<sup>e,\*</sup>,  
Eliana P. Calvo<sup>e</sup>, Melchor Álvarez-Mon<sup>f</sup>, Didier Musso<sup>g</sup>

<sup>a</sup> Grupo de Investigación Enfermedades Infecciosas y Control de Infecciones, Hospital Universitario de Sincelejo, Sincelejo, Sucre, Colombia

<sup>b</sup> Doctorate in Tropical Medicine Program, Universidad del Atlántico, Barranquilla, Atlántico, Universidad de Cartagena, Bolívar, Colombia

<sup>c</sup> Public Health and Infection Research Group, Faculty of Health Sciences, Universidad Tecnológica de Pereira, Pereira, Risaralda, Colombia

<sup>d</sup> Department of Gynecology, Clínica Santa María, Sincelejo, Sucre, Colombia

<sup>e</sup> Grupo de Virología, Universidad El Bosque, Bogotá, DC, Colombia

<sup>f</sup> Department of Immune System Diseases and Oncology, University Hospital "Príncipe de Asturias", Alcalá University, Madrid, Spain

<sup>g</sup> Unit of Emerging Infectious Diseases, Institut Louis Malardé, Papeete, French Polynesia

## ARTICLE INFO

## Article history:

Received 1 July 2016

Received in revised form 25 July 2016

Accepted 30 July 2016

**Corresponding Editor:** Eskild Petersen, Aarhus, Denmark.

## Keywords:

Dengue

Chikungunya

Zika

Co-infection

Pregnancy

## SUMMARY

The clinical findings of a pregnant woman from Colombia with a triple co-infection caused by dengue, chikungunya, and Zika viruses are described. Weekly obstetric ultrasounds from 14.6 to 29 weeks of gestation were normal. She remains under follow-up and management according to the standard guidelines for the management of Zika virus-infected pregnant women.

© 2016 The Authors. Published by Elsevier Ltd on behalf of International Society for Infectious Diseases. This is an open access article under the CC BY-NC-ND license (<http://creativecommons.org/licenses/by-nc-nd/4.0/>).

## 1. Introduction

Dengue virus (DENV), chikungunya virus (CHIKV), and Zika virus (ZIKV) are arboviruses that cause ongoing epidemics in several countries of Latin America and the Pacific.<sup>1,2</sup> CHIKV, DENV, and ZIKV affect pregnancies, with a wide observed spectrum of outcomes. Adverse outcomes of CHIKV infections in pregnancy have been reported in Colombia and on the island of La Réunion, primarily encephalopathy.<sup>3</sup> Severe dengue has been reported in pregnant women.<sup>4</sup> There is a growing body of evidence suggesting that ZIKV is responsible for severe congenital complications mainly consisting of microcephaly.<sup>5</sup> The extent of congenital complications related to ZIKV is, however, still a matter of debate,

principally because only a small proportion of cases have been investigated fully.<sup>5</sup>

Co-infections with these three viruses have been reported,<sup>6</sup> but the effect of co-infections during pregnancy is unknown. In addition, in the context of the current ZIKV outbreak, which has become the focus of much attention, other pathogens with a potential impact in pregnancy may receive less attention. The case of a pregnant woman with molecular confirmation of a triple co-infection caused by DENV, CHIKV, and ZIKV is reported herein.

## 2. Case report

A 33-year-old woman from Sincelejo, Sucre, Colombia, an area known to have active co-circulation of DENV serotypes 1–4, CHIKV, and ZIKV,<sup>6</sup> presented at 14.6 weeks of her third pregnancy with a clinical illness, that consist of non-purulent bilateral conjunctivitis, an intense pruritic maculopapular rash on the upper limbs, thorax, and abdomen, a headache, mild-to-intense bilateral metacarpophalangeal and wrist arthralgia, and limb edema, particularly of

\* Corresponding author.

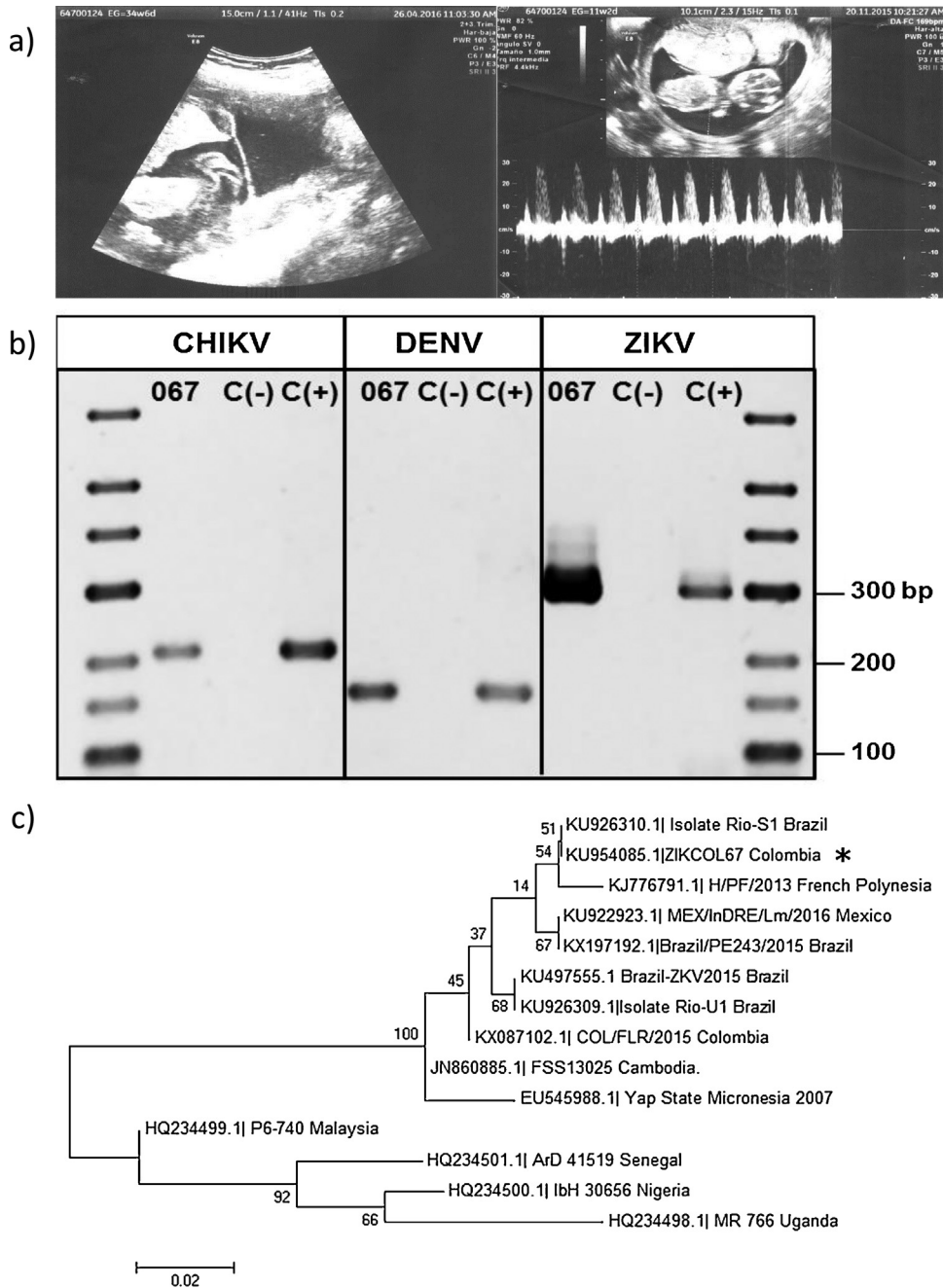
E-mail address: [castellanosjaime@unbosque.edu.co](mailto:castellanosjaime@unbosque.edu.co) (J.E. Castellanos).

<sup>1</sup> Wilmer E. Villamil-Gómez and Alfonso J. Rodríguez-Morales contributed equally to this article.

the ankles, 1 day before consultation. She denied myalgia, retro-orbital pain, hemorrhages, or abdominal pain. She reported that arboviral infections had not affected her or her family.

The patient had previously been referred with a provisional diagnosis of mitral valve prolapse in 2013. She had normal electrocardiogram findings, and an echocardiogram confirmed the diagnosis. She had a history of umbilical hernia in 2012 and cholecystitis in 2015, leading to a cholecystectomy. She had a single spontaneous abortion in early 2014 and had previously given birth to a healthy female infant by uncomplicated vaginal delivery in 2007. She did not report any history of blood transfusion or organ transplant.

Thick and thin blood smears for malaria were negative. Physical examination revealed cervical lymphadenopathy, non-purulent conjunctivitis, bipalpebral edema, and painful edema in the lower limbs, with an extensive maculopapular rash affecting the upper and lower limbs and abdomen, with Pastia lines (Thompson's sign). She did not have hepatomegaly or splenomegaly, either clinically or on ultrasound, either at presentation or during follow-up (Figure 1a). Her pulse rate was 88 beats/min, blood pressure was 100/60 mmHg, and temperature was 36.7 °C. A holosystolic murmur was heard on cardiac auscultation. A neurological examination was normal. Obstetric ultrasound findings were normal for gestational age, with a biparietal diameter of



**Figure 1.** Findings in the pregnant woman from Colombia co-infected with Zika (ZIKV), dengue (DENV), and chikungunya (CHIKV). (a) Ultrasounds at 29 weeks of gestation, showing no alterations. (b) Agarose gel analysis of PCR products for DENV, CHIKV, and ZIKV (067, patient samples; C(-), negative control; C(+), positive control, supernatants of infected cultures). (c) Phylogenetic analysis of nucleic acid sequences was performed using 250 nucleotides of the ZIKV envelope protein. GenBank accession numbers for the complete genomes are given. The tree was inferred using the maximum likelihood algorithm based on the Tamura-parameter model as implemented in MEGA 6. The numbers shown to the left of the nodes represent bootstrap support values (1000 replicates). The asterisk indicates the sample isolated and reported in this article.

29.7 mm, fetal length of 16.9 cm, estimated fetal weight of 144 g, and fetal heart rate of 144 beats/min, with a grade 1 anterior placenta, no physical abnormalities, and all four cardiac chambers noted. She was mildly anemic with a hemoglobin of 11.5 g/dl (normal range 12.0–14.5 g/dl) and lymphopenic with a lymphocyte count of  $1.03 \times 10^9$  cells/l (normal range  $1.2\text{--}3.2 \times 10^9$  cells/l). She had an elevated erythrocyte sedimentation rate (ESR) (45 mm/1 h, normal range 1–15 mm/1 h), a normal creatine phosphokinase level (57 IU/l, normal range 26–140 IU/l), and normal transaminase levels (aspartate aminotransferase (AST) 40 IU/l, normal range 10–40 IU/l; alanine aminotransferase (ALT) 56 IU/l, normal range 7–56 IU/l).

A blood sample was collected on day 3 after the onset of symptoms for virological analysis to detect DENV, CHIKV, and ZIKV RNA. A triple nested reverse transcription (RT) PCR was used to amplify DENV-2, Asian genotype CHIKV, and Asian lineage ZIKV RNA (Figure 1b). The specificity of the amplification was confirmed by sequencing. The phylogenetic tree is shown in Figure 1c. The amplification protocol is described in the Appendix.

The patient was initially managed with acetaminophen (500 mg every 6 h), loratadine (10 mg every 24 h), 10-min ice massages applied to painful areas and 20-min use of heat pads (every 1 h), topical calamine (every 6 h), and folic acid (5 mg every 8 h). Subsequently, at 10 days, most of the clinical manifestations had subsided, except for the wrist arthralgia and skin rash (these had improved significantly 9 weeks later). Her ESR decreased to 17 mm. Weekly obstetric ultrasounds from 14.6 weeks to 29 weeks of gestation were normal. The patient remains under follow-up and management according to the standard national and international protocols, particularly for Zika during pregnancy.

### 3. Discussion

The clinical presentation of ZIKV infections is non-specific. ZIKV infections may be confused with infections caused by other arboviruses that co-circulate in ZIKV endemic areas, especially DENV and CHIKV.<sup>2</sup> Co-infection of ZIKV and other arboviruses has already been reported: with DENV and CHIKV in Colombia,<sup>6</sup> and with DENV in French Polynesia and New Caledonia.<sup>2</sup> However, it appears that arbovirus co-infection during pregnancy has not been reported previously. The impact of arbovirus co-infection on patient outcomes is unknown, but a fatal co-infection with DENV and CHIKV has been reported in Colombia.<sup>7</sup> During pregnancy, ZIKV may cause severe damage to the fetus but not to the pregnant woman. However, it is important to recognize maternal DENV infections because pregnant women are at increased risk of developing severe dengue.<sup>4</sup> It is also important to recognize CHIKV infections because encephalopathy in neonates has been associated with CHIKV infections<sup>3</sup> and ZIKV infections in Martinique.<sup>8</sup>

Several guidelines have been formulated to assist clinicians in assessing ZIKV in patients with DENV- and CHIKV-negative samples and in those who are negative on sequential testing for both pathogens.<sup>9,10</sup> However, even if these guidelines are followed, co-infections may be missed. Where these viruses co-circulate, especially in the Americas and Pacific, multiplex arbovirus detection including ZIKV, CHIKV, and DENV should be implemented for at-risk patients, including pregnant women, employing the same recommendations that have been issued for the screening of blood donors.<sup>2,11</sup> A commercial multiplex molecular assay detecting ZIKV, CHIKV, and DENV has recently been accredited by the US Food and Drug Administration and may be used in routine practice.

ZIKV is responsible for severe fetal and neonatal complications, especially microcephaly, but the risk of microcephaly related to ZIKV has yet to be defined due to reporting bias.<sup>12</sup> Several infections may cause microcephaly, including the pathogens

associated with the teratogenic effect summarized by the acronym TORCH.<sup>5</sup> Unfortunately, TORCH pathogen infections also have non-specific clinical presentations and may be asymptomatic. In the context of the ZIKV outbreak, there is a risk that clinicians will focus on ZIKV at the expense of other causes of microcephaly. During ZIKV outbreaks the incidence of the infection may be high. In French Polynesia, for instance, 2.8% of asymptomatic blood donors tested positive for ZIKV RNA during that outbreak.<sup>2</sup> Even if ZIKV RNA is detected, other infections should be considered, and the detection of ZIKV in microcephalic newborns does not exclude other causes of this malformation. To date there is no specific treatment for ZIKV infections during pregnancy, whereas specific treatments have been proposed for other TORCH pathogens, including Toxoplasma and cytomegalovirus.<sup>5</sup> Other causes of microcephaly including genetic factors should also be investigated carefully to facilitate genetic counseling. ZIKV may cause other central nervous system malformations that may be found in TORCH pathogen infections<sup>5</sup>, and the occurrence of co-infections should be investigated carefully.

Since the World Health Organization declared the ZIKV epidemic a Public Health Emergency of International Concern, the major focus has been on ZIKV – other pathogens have been neglected. Even if ZIKV RNA is detected, this does not exclude the possibility of other infections.

Because ZIKV infection clinically resembles DENV and CHIKV infections, which co-circulate in most of the ZIKV endemic areas and are also responsible for maternofetal infections, it is recommended that all symptomatic pregnant women should be tested for ZIKV, CHIKV, and DENV, even if ZIKV has already been detected.

Finally, the case presented here suggests that co-infection should be considered in travelers visiting areas where these arboviruses co-circulate.

### Acknowledgements

We thank Dr Michael E. Jones (former Consultant in Infectious Diseases, Regional Infectious Diseases Unit, Western General Hospital, Edinburgh, Scotland, UK) for his critical review of the manuscript, particularly of the English language and style.

*Financial support:* This work was supported by the Hospital Universitario de Sincelejo, Universidad El Bosque, and Universidad Tecnológica de Pereira. Universidad El Bosque was responsible for the publication fees.

*Conflict of interest:* All authors report no potential conflicts of interest.

### Appendix

The reverse transcription and first amplification round (multiplex) was performed with three outer oligo pairs and the SuperScript III One-Step RT-PCR Kit (Invitrogen). The ZIKV outer primers were designed on gene E: ZF944 5'-GGT CAT GAT ACT GCT GAT TGC, and ZR1269 5'-CCA CTA ACG TTC TTT TGC AGA C (which align with Latin American isolates). CHIKV outer primers were designed on the E1 gene: CHK-F10240 5'-ACG CAA TTG AGC GAA GCA C, and CHK-R10541 5'-CCA AAT TGT CCY GGT CTT CCT (which have been reported previously). DENV was amplified using primers mD1–D2 reported previously.

The second-round amplification (nested) was carried out in separate tubes for each virus using 2 µl of first amplicon, the above-mentioned reverse primers, and a new forward inner primer annealing inside the amplicon. These inner forward primers were ZR1241 5'-AGT GTC TGA CTG CTT GTC AAG G for ZIKV, CHK-R10444 5'-CTG AAG ACA TTG GCC CCA C for CHIKV. For DENV, a

mix of the D1 reverse primer and forward primers TS1 5'-CCC GTA ACA CTT TGA TCG C, TS2 5'-CGC CAC AAG GGC CAT GAA CAG TTT, TS3 5'-TAA CAT CAT CAT GAG ACA GAG C, and TS4 5'-TTC TCC CGT TCA GGA TGT TC was used. Amplification products were separated by agarose electrophoresis and stained with ethidium bromide. Positive controls were both culture supernatants of infected C6/36 cells (DENV) or Vero cells (CHIKV) and serum of previously confirmed infections for DENV, CHIKV, and ZIKV. Supernatant of non-infected C6/36 and serum from healthy donors were used as negative controls. ZIKV and CHIKV amplification products were confirmed by sequencing the E encoding gene for ZIKV and the E1 encoding gene for CHIKV (Asian genotype). The second round of amplification identified DENV serotype 2.

## References

- Rodríguez-Morales AJ. Zika: the new arbovirus threat for Latin America. *J Infect Dev Ctries* 2015;**9**:684–5.
- Musso D, Gubler DJ. Zika virus. *Clin Microbiol Rev* 2016;**29**:487–524.
- Gérardin P, Barau G, Michault A, Bintner M, Randrianaivo H, Choker G, et al. Multidisciplinary prospective study of mother-to-child chikungunya virus infections on the island of La Réunion. *PLoS Med* 2008;**5**:e60. <http://dx.doi.org/10.1371/journal.pmed.0050060>
- Machado CR, Machado ES, Rohloff RD, Azevedo M, Campos DP, de Oliveira RB, Brasil P. Is pregnancy associated with severe dengue?. A review of data from the Rio de Janeiro surveillance information system. *PLoS Negl Trop Dis* 2013;**7**:e2217.
- Panchaud A, Stojanov M, Ammerdorffer A, Vouga M. Emerging role of Zika virus in adverse fetal and neonatal outcomes. *Clin Microbiol Rev* 2016;**29**:659–94.
- Villamil-Gómez WE, González-Camargo O, Rodríguez-Ayubi J, Zapata-Serpa D, Rodríguez-Morales AJ. Dengue, chikungunya and Zika co-infection in a patient from Colombia. *J Infect Public Health* 2016. <http://dx.doi.org/10.1016/j.jiph.2016.07.001>
- Mercado M, Acosta-Reyes J, Parra E, Pardo L, Rico A, Campo A, et al. Clinical and histopathological features of fatal cases with dengue and chikungunya virus co-infection in Colombia, 2014 to 2015. *Euro Surveill* 2016;**21**. <http://dx.doi.org/10.2807/1560-7917.ES.2016.21.22.30244>. pii=30244.
- Rozé B, Najioullah F, Signate A, Apetse K, Brouste Y, Gourgoudou S, et al. Zika virus detection in cerebrospinal fluid from two patients with encephalopathy, Martinique, February 2016. *Euro Surveill* 2016;**21**. <http://dx.doi.org/10.2807/1560-7917.ES.2016.21.16.30205>. pii=30205.
- World Health Organization. Laboratory testing for Zika virus infection. Interim guidance 23 March 2016. WHO/ZIKV/LAB/16.1. WHO; 2016.
- Pan American Health Organization. Algorithm for detecting Zika virus. PAHO; 2016.
- Musso D, Stramer SL, Bush MP. Zika virus: a new challenge for blood transfusion. *Lancet* 2016;**387**:1993–4.
- Samarasekera U, Triunfol M. Concern over Zika virus grips the world. *Lancet* 2016;**387**:521–4.