



Case Report

Disseminated penicilliosis due to *Penicillium chrysogenum* in a pediatric patient with Henoch–Schönlein syndrome

Martha Avilés-Robles^{a,*}, Carlos Gómez-Ponce^a, Jesús Reséndiz-Sánchez^b,
Aída Verónica Rodríguez-Tovar^c, Adrián Ceballos-Bocanegra^d, Ángeles Martínez-Rivera^c

^a Department of Infectious Diseases, Hospital Infantil de México Federico Gómez, Dr. Márquez #162, Col. Doctores, Cuauhtémoc, 06720 Mexico City, Mexico

^b Laboratory of Mycology, Hospital Infantil de México Federico Gómez, Mexico City, Mexico

^c Department of Microbiology, ENCB, Instituto Politécnico Nacional, Mexico City, Mexico

^d Department of Pediatrics, Centro Medico Dalinde, Mexico City, Mexico

ARTICLE INFO

Article history:

Received 12 May 2016

Received in revised form 25 July 2016

Accepted 27 August 2016

Corresponding Editor: Eskild Petersen,
Aarhus, Denmark

Keywords:

Penicillium chrysogenum

Penicilliosis

Hyalohyphomycosis

Disseminated penicilliosis

SUMMARY

A case of disseminated infection caused by *Penicillium chrysogenum* in a 10-year-old boy with a history of Henoch–Schönlein purpura and proliferative glomerulonephritis, treated with immunosuppressors, is reported herein. The patient had a clinical picture of 2 weeks of fever that did not respond to treatment with broad-spectrum antibiotics and amphotericin B. Computed tomography imaging showed diffuse cotton-like infiltrates in the lungs, hepatomegaly, mesenteric lymphadenopathy, and multiple well-defined round hypodense lesions in the spleen. His treatment was changed to caspofungin, followed by voriconazole. One month later, a splenic biopsy revealed hyaline septate hyphae of $> 1 \mu\text{m}$ in diameter. Fungal growth was negative. However, molecular analysis showed 99% identity with *P. chrysogenum*. A therapeutic splenectomy was performed, and treatment was changed to amphotericin B lipid complex and caspofungin. The patient completed 2 months of treatment with resolution of the infection. *P. chrysogenum* is a rare causative agent of invasive fungal infections in immunocompromised patients, and its diagnosis is necessary to initiate the appropriate antifungal treatment.

© 2016 The Authors. Published by Elsevier Ltd on behalf of International Society for Infectious Diseases. This is an open access article under the CC BY-NC-ND license (<http://creativecommons.org/licenses/by-nc-nd/4.0/>).

1. Introduction

The genus *Penicillium* comprises approximately 225 species, including *P. chrysogenum*. They are found in soil, wood, decaying vegetation, and because of their dry, one-celled conidia they are airborne. *Penicillium* species have low pathogenicity and rarely cause infections. The one exception is *P. marneffeii*, which is endemic in Southeast Asia. *P. chrysogenum* have been reported as an unusual cause of invasive infection mainly seen in immunocompromised hosts.

2. Case report

The case of a 10-year-old male with terminal chronic renal failure secondary to Henoch–Schönlein purpura and diffuse endocapillary proliferative glomerulonephritis is reported. He was treated with

methylprednisolone, cyclophosphamide, mycophenolate mofetil, and azathioprine for 9 months and received prednisone and underwent hemodialysis for 2 months prior to admission.

The patient was admitted due to a fever lasting 2 days, odynophagia, watery rhinorrhea, and a cough. Physical examination revealed generalized pallor and two ulcerated lesions with erythematous borders in the oral cavity. No cardiopulmonary alterations were found, and the abdomen was soft. A complete blood count analysis showed hemoglobin of 7.4 g/dl, leukocytes $0.3 \times 10^9/\text{L}$, absolute neutrophil count $0.011 \times 10^9/\text{L}$, absolute lymphocyte count $0.264 \times 10^9/\text{L}$, and platelets $10 \times 10^9/\text{L}$. The immunosuppressive therapy was stopped and antibiotic treatment was started with cefotaxime (150 mg/kg/day) and dicloxacillin (100 mg/kg/day). The fever persisted after 3 days of treatment; therefore, the antibiotic regimen was changed to cefepime (150 mg/kg/day) plus amikacin (15 mg/kg/day). The fever continued to persist after 6 days of hospitalization without evidence of new infectious foci, and the blood count continued to show neutropenia. The antibiotic regimen was changed to meropenem (60 mg/kg/day). On day 13, the patient continued to exhibit

* Corresponding author. Tel.: +52 1 55 5228-9917 ext. 2331.
E-mail address: marmtom@hotmail.com (M. Avilés-Robles).

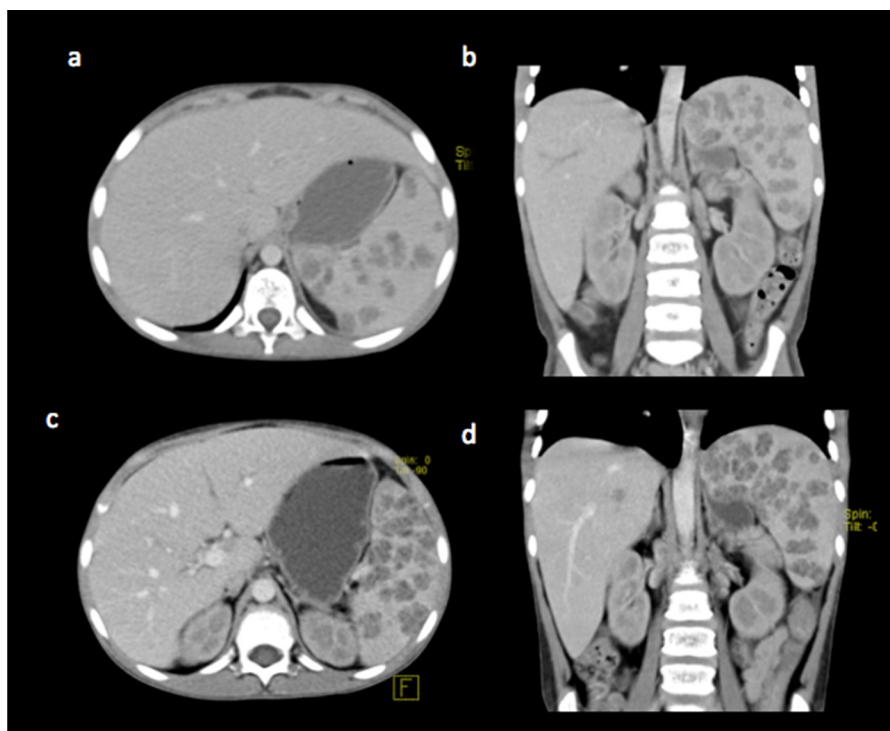


Figure 1. (a) Axial and (b) coronal contrast-enhanced computed tomography (CECT) abdominal sections showing hepatomegaly and multiple hypodense round lesions in the spleen that did not enhance after the administration of intravenous contrast agent. (c) Axial and (d) coronal CECT sections showing persistence of the hepatomegaly and progression of the spleen lesions.

neutropenia and fever, and there was new onset of abdominal pain radiating in a belt-like fashion. His lipase concentration was 10 055 U/l, and amylase concentration was 1150 U/l. The administration of amphotericin B lipid complex was started at a dose of 5 mg/kg/day. Due to the persistent fever after 14 days of amphotericin B treatment, a computed tomography (CT) scan was performed. This showed diffuse cotton-like infiltrates in the posterior pulmonary segments (predominantly on the right side), bilateral pleural effusion, hepatomegaly, mesenteric lymphadenopathy, and multiple well-defined round hypodense lesions in the spleen that did not enhance after the administration of intravenous contrast agent (Figure 1 a, b). Caspofungin was started at a dose of 70 mg/m² body surface/day (loading dose) and 50 mg/m² body surface/day (maintenance dose) due to the persistent fever and lesions observed on CT. The fever subsided after 5 days of treatment with caspofungin. After 21 days of caspofungin treatment, the medication was changed to oral voriconazole and the patient was discharged to complete his treatment on an ambulatory basis.

After 37 days of outpatient treatment, a CT scan was obtained during a follow-up visit. This showed progression of the multiple hypodense heterogeneous lesions in the spleen and a hypodense lesion on the posterior aspect of the pancreas (Figure 1 c, d). The patient was hospitalized for a spleen biopsy and treatment with voriconazole was continued. The surgical finding was a congestive spleen with pus. The following tests were performed: Gram staining, which did not show bacteria; direct examination with 10% potassium hydroxide, which showed abundant hyaline septate hyphae of > 1 μm in diameter. There was no growth of bacteria or fungi in splenic tissue cultures. The pathology report showed splenic tissues with numerous areas of necrosis and abundant neutrophilic exudates surrounded by a palisade of epithelioid macrophages and multinucleated giant cells. Some micelles and yeasts could be seen, as well as some areas of fibrosis, granuloma without necrosis, and abundant macrophages with

hemosiderin. A sample was sent to the Laboratory of Medical Mycology of the National School of Biological Sciences for molecular analysis by sequencing of the internal transcribed spacer (ITS) (ITS1–5.8-rDNA–ITS2) using universal primers.¹ The amplified fragment was sequenced and analyzed with the Basic Local Alignment Search Tool (BLAST) to determine its identity. The nucleotide sequence of the ITS region (600 bp) presented 99.3% similarity with *Penicillium chrysogenum*.

Treatment with voriconazole was suspended, and caspofungin plus amphotericin B was reinitiated. A CT scan performed after almost 2 months of combined antifungal treatment showed that only the heterogeneous hypodense confluent spleen lesions persisted. A splenectomy was performed, and antifungals were suspended 14 days later, resulting in the completion of a total of 61 days of treatment. The patient was discharged and monitored by CT. He has remained asymptomatic and disease-free for 2 years.

3. Discussion

Penicillium is one of the most abundant environmental mesophilic genera found in nature. *P. chrysogenum* is widely distributed in the environment; its spores are found in house dust, damp buildings, and decomposing vegetables, fruits, bread, and nuts. Humans are frequently exposed to the air-borne spread of *P. chrysogenum* spores.

P. chrysogenum can be an allergen, produce skin reactivity, and colonize the airways of patients with respiratory allergies. It is a thermotolerant fungus; therefore, it has been described as a human pathogen despite its low pathogenicity. There are reported cases of skin infections, esophagitis, keratitis, endophthalmitis, pneumonia, endocarditis, central nervous system infections, and even rare cases of disseminated infection in immunocompromised patients.^{2,3} *P. chrysogenum* can grow at body temperature and is thought to cause disseminated infections both through the blood

and by direct mucosal invasion due to the different types of infections with which it has been associated.

Although *Aspergillus spp* are the leading filamentous fungi causing invasive infections in immunocompromised patients, the number of reported cases of invasive infection by other filamentous fungi, such as *Fusarium spp*, *Scedosporium spp*, *Penicillium spp*, and *Acremonium spp*, has increased in the last decade. *Penicillium* and *Aspergillus* belong to the family *Aspergillaceae*; both show reactivity with the rat EBA-2 monoclonal antibody used in the galactomannan assay. There are no clear indicators specific for *Penicillium* infection that can be identified in the patient's history or on physical examination, and it can cause a wide spectrum of disease. A clinical suspicion of infection with *Penicillium* should be considered in the differential diagnosis in the presence of hyaline septate hyphae upon direct examination or in pathology specimens.

The identification of fungal pathogens based on phenotypic characteristics is challenging because it requires well-trained personnel and adequate samples. In recent years, molecular-based techniques, especially DNA sequencing, have been implemented for the identification of fungi. Numerous targets within the fungal genome have been evaluated using sequence areas within the ribosomal DNA. The ITS region has the broadest range for fungal identification and is accepted as the primary fungal barcode.⁴ However, as some phylogenetically closely-related fungal species differ in only a few or one nucleotide position, ITS may not be efficacious for distinguishing between closely-related fungal species. Amplification-based ITS assays to identify fungal infections could potentially impact treatment and improve the outcomes for affected patients if they are accessible to clinicians.

Currently, there is no antibiotic of choice for the management of penicilliosis. Case reports exist of successful treatment of opportunistic infections of *P. chrysogenum* and other species of *Penicillium* with amphotericin B, itraconazole, or fluconazole. In vitro studies have documented the susceptibility of *Penicillium* species to posaconazole, voriconazole, and ravuconazole. Caspofungin has shown moderate in vitro activity against *Penicillium*

spp.⁵ The duration of treatment is not standardized. Case reports have been published of disseminated infections caused by *P. chrysogenum* and *Penicillium marneffeii* that have responded well to intravenous treatment with amphotericin B and that were subsequently managed on an outpatient basis with oral itraconazole for several weeks. However, treatment failures with amphotericin B have also been reported.

In conclusion, this appears to be the first report of disseminated infection of *P. chrysogenum* in a pediatric patient in Mexico. *P. chrysogenum* has emerged as an opportunistic pathogen in immunocompromised patients, but its role as the causative agent of invasive infections in children is poorly documented. It is necessary to maintain a high level of suspicion for the disease to apply the necessary diagnostic strategies and initiate the appropriate antifungal treatment.

Acknowledgements

Aída Verónica Rodríguez-Tovar and María Angeles Martínez Rivera are EDI, COFAA, Instituto Politécnico Nacional (IPN) and SIN, CONACYT, México fellows.

Ethical approval: Ethical approval was not required.

Conflict of interest: Nothing to declare.

References

1. Gardes M, Bruns TD. ITS primers with enhanced specificity for basidiomycetes—application to the identification of mycorrhizae and rusts. *Mol Ecol* 1993;**2**:113–8.
2. Duong TA. Infection due to *Penicillium marneffeii*, an emerging pathogen: review of 155 reported cases. *Clin Infect Dis* 1996;**23**:125–30.
3. Kantarcioglu AS, Apaydin H, Yücel A, de Hoog GS, Samson RA, Vural M, et al. Central nervous system infection due to *Penicillium chrysogenum*. *Mycoses* 2004;**47**:42–8.
4. Schoch CL, Seifert KA, Huhndorf S, Robert V, Spouge JL, Levesque CA, et al. Nuclear ribosomal internal transcribed spacer (ITS) region as a universal DNA barcode marker for fungi. *Proc Natl Acad Sci U S A* 2012;**109**:6241–6.
5. Diekema DJ, Messer SA, Hollis RJ, Jones RN, Pfaller MA. Caspofungin, itraconazole, posaconazole, ravuconazole, voriconazole, and amphotericin B against 448 recent clinical isolates of filamentous fungi. *J Clin Microbiol* 2003;**41**:3623–6.