



ELSEVIER

Contents lists available at ScienceDirect

## International Journal of Infectious Diseases

journal homepage: [www.elsevier.com/locate/ijid](http://www.elsevier.com/locate/ijid)

## Case Report

## Successful Treatment of a Patient With Severe COVID-19 Using an Integrated Approach Addressing Mast Cells and Their Mediators

Theoharis C. Theoharides<sup>1,2,3,4,\*</sup>, Lucy Guerra<sup>5</sup>, Kapilkumar Patel<sup>6</sup><sup>1</sup>Laboratory of Molecular Immunopharmacology and Drug Discovery, Department of Immunology, Tufts University School of Medicine, Boston, MA, USA<sup>2</sup>School of Graduate Biomedical Sciences, Tufts University School of Medicine, Boston, MA, USA<sup>3</sup>Department of Internal Medicine, Tufts University School of Medicine and Tufts Medical Center, Boston, MA, USA<sup>4</sup>Institute of Neuro-Immune Medicine, Nova Southeastern University, Tampa FL, USA<sup>5</sup>Department of Medicine, University of South Florida Morsani College of Medicine, Tampa General Hospital, Tampa, FL, USA<sup>6</sup>Center for Advanced Lung Disease and Lung Transplant Program, Division of Pulmonary and Critical Care Medicine, University of South Florida, Morsani College of Medicine, Tampa General Hospital, Center, Tampa, FL, USA

## ARTICLE INFO

## Article history:

Received 10 December 2021

Revised 21 February 2022

Accepted 22 February 2022

## Keywords:

Coronavirus

Fibrosis

Flavonoids

Inflammation

Lungs

Mast Cells

Treatment

This is the case of a 49-year-old Caucasian female subject whose only significant medical history was in situ breast cancer. She tested positive for COVID-19 on November 30, 2020, and complained of dyspnea and fatigue.

The patient was admitted to the hospital on December 20, 2020, severely hypoxic with a diagnosis of acute respiratory failure. Initial bloodwork showed significantly reduced oxygen saturation ( $O_2$  saturation = 42%,  $PO_2$  = 29,  $PCO_2$  = 56,  $HCO_3$  = 34). C-reactive protein (CRP) and erythrocyte sedimentation rate (ESR) were elevated. Lung computed tomography (CT) showed peripheral nodular and ground glass opacities in the lung bases, indicative of diffuse inflammation, and she was given the diagnosis of acute hypoxic respiratory failure due to COVID-19. She was treated with azithromycin, ceftriaxone, albuterol, dexamethasone, and convalescent plasma but was not intubated. She was discharged on December 15, 2020, with the diagnosis of acute hypoxic respiratory

failure secondary to COVID-19 pneumonia, and she was prescribed dexamethasone and tizanidine for muscle spasms.

She was prescribed home oxygen, 2 liters (L) by nasal cannula (nc). However, on December 13, 2020, the patient's oxygen levels dropped and stayed at around 70% saturation, prompting her to visit the walk-in COVID-19 clinic, and from there, she was transported by ambulance to the emergency room (ER), where she was discharged on 10 L oxygen by nc. On January 6, 2021, the patient went back to the ER where she coughed up a blood clot. Chest radiogram, CT of the lungs, and CT angiogram of the pulmonary arteries were normal with no evidence of acute pulmonary embolism. The echocardiogram was also normal. The patient was discharged with no further treatment recommendations.

On January 20, 2021, the patient again visited the COVID-19 clinic. She was noted to have decreased distal pulses and was referred for high resolution CT and pulmonary function test with diffusing capacity for carbon monoxide (DLCO). On February 5, 2021, the high-resolution CT scan showed some scarring/atelectasis in the right middle lobe. The pulmonary function test performed on February 9, 2021 was normal, but DLCO was abnormal. She was prescribed albuterol.

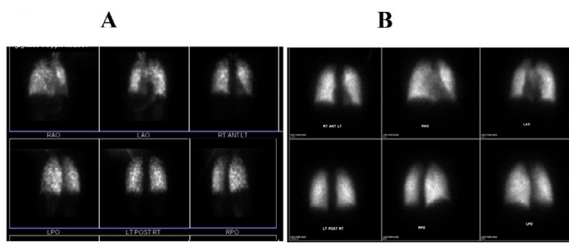
**Abbreviations:** ESR, Erythrocyte sedimentation rate; CT, Computed tomography; MRI, Magnetic resonance imaging; NC, Nasal cannula.

\* Corresponding author: Theoharis C. Theoharides, MS, MPhil, PhD, MD, Department of Immunology, Tufts University School of Medicine, 136 Harrison Avenue, Suite 304, Boston, MA 02111, USA, Phone: (617) 636-6866, Fax: (617) 636-2456.

E-mail address: [theoharis.theoharides@tufts.edu](mailto:theoharis.theoharides@tufts.edu) (T.C. Theoharides).

<https://doi.org/10.1016/j.ijid.2022.02.049>

1201-9712/© 2022 The Authors. Published by Elsevier Ltd on behalf of International Society for Infectious Diseases. This is an open access article under the CC BY license (<http://creativecommons.org/licenses/by/4.0/>)



**Fig. 1.** Lung Ventilation-perfusion (V/Q) scan images. (A) Before Treatment (March 2, 2021) showing coarse heterogeneous perfusion of the lungs bilaterally, suggestive of the presence of diffuse inflammation and micro thromboembolic disease; (B) After Treatment (August 6, 2021) showing minimal heterogeneity of uptake.

In the following weeks, in addition to the breathing difficulty, the patient felt extremely fatigued with severe brain fog that necessitated leaving her demanding professional job. Oxygen saturation was in the low 90s% at rest and in mid-70s%–mid-80s% when ambulating even at 10 L nc oxygen administration.

The cardiac magnetic resonance imaging (MRI) performed on February 16, 2021, was normal, but the cardiologist prescribed rivaroxaban. A ventilation-perfusion (V/Q) scan done on March 1, 2021, revealed coarse heterogeneous perfusion of the lungs bilaterally, suggestive of the presence of diffuse inflammation and microthromboembolic disease (Fig. 1A); these findings correlated to those of chest radiograms. The patient was referred to the Center for Advanced Lung Disease and Lung Transplant Program, where it was noted that the clots were apparently fossilized and deep within the lungs, rendering a thromboendarterectomy not a viable option. The patient remained on 10 L pc oxygen supplementation while ambulating.

A close friend of the patient was a fellow graduate from the Harvard Kennedy School with 1 of the authors (TCT), who happened to deliver a lecture on the role of mast cells in COVID-19 (Theoharides, 2020a) while on sabbatical leave at Nova Southeastern University at the Tampa campus, and she approached him for advice. On review of the medical history, it became apparent that the patient was very sensitive to histamine-rich foods, consumption of which promptly resulted in mouth pruritus and swelling, suggestive of mast cell activation. Interestingly, such hypersensitivity symptoms along with cognitive dysfunction are similar to those experienced by patients with mast cell activation syndrome (MCAS) (Theoharides and Conti, 2020; Afrin, et al., 2020). Moreover, mast cell activation symptoms are increased in patients with Long COVID (Weinstock, et al., 2021).

On March 10, 2021, the patient was started on an integrative treatment regimen aimed at inhibiting the release of proinflammatory, prothrombotic, and fibrotic mediators, mostly from mast cells, while increasing oxygen transport capacity and reducing brain fog.

- Acetyl salicylic acid (ASA, 81 mg/day) was added to rivaroxaban to prevent the development of microthromboses.
- The dual histamine-1 and platelet activating factor (PAF) antagonist rupatadine (Rupall, available in Canada, 10 mg, twice per day) was used because it also inhibits the action of PAF, which may contribute to microthrombi (Demopoulos, et al., 2020) and the release of proinflammatory cytokines from mast cells (Alevizos M, et al., 2013).
- The histamine-2 receptor antagonist famotidine was added because not only was it reported to improve clinical outcomes in hospitalized patients with COVID-19 (Freedberg, et al., 2020), but also because it suppresses mast cell activation (Shah, et al., 1994).
- The prostaglandin E1 analogue misoprostol (Cytotec, 100 mcg/day) was added because it is antifibrotic and decreases mast cell activation (Shah, et al., 1994).

- Vitamin D3 (5,000 IU/day) was added because low levels have been associated with severe course of COVID-19 (Karonova, et al., 2021), and because Vitamin D3 can regulate atopic reactions (Theoharides, 2017), especially mast cell activation (Yip, et al., 2014; Liu, et al., 2017).
- Erythropoietin (100 units/kg subcutaneous injection, thrice per week for 12 weeks) was added, even though there was no anemia, to improve oxygenation to the brain and lungs (Ehrenreich, et al., 2020).
- Methyl prednisolone (4 mg/day) was used to reduce inflammation and protect vascular integrity.
- Two dietary supplements (formulated in olive pomace oil to increase oral absorption), 1 containing the natural flavonol quercetin and the structurally related flavone luteolin (FibroProtek®) and the other containing luteolin, calcium folinate, hydroxytyrosol, and berberine (BrainGain®) were also used as 2 softgels of each, twice per day.

These flavonoids have anti-inflammatory properties and inhibit mast cells (Theoharides, 2020a). They have also been proposed as prophylaxis or treatment against COVID-19 (Theoharides, 2020a; Di, et al., 2021). In particular, a number of studies using in silico approaches identified quercetin and luteolin as potential strong blockers of SARS-CoV-2 spike protein's receptor binding domain (RBD) attaching to the angiotensin-converting enzyme 2 (ACE2) receptor (Shadrack, et al., 2021). Berberine, also contained in BrainGain, suppressed expression of SARS-CoV-2-related receptors and cytokines (Wang, et al., 2021).

The patient's condition gradually improved to the point that no oxygen was required except on occasion. A brain single positron emission (SPECT) scan done on August 4, 2021 was normal and a repeat V/Q perfusion scan performed on August 6, 2021 showed minimal, if any, heterogeneity of uptake (Fig. 1B). The patient's clinical examination was normal and oxygen saturation was maintained at over 95%. As a result, the patient was taken off the lung transplant list.

The SARS-CoV-2 infects cells by first binding to ACE2, leading to a complex immune response (Zhou, et al., 2020) that, in most cases, involves the release of proinflammatory chemokines and cytokines, leading to the development of the clinical presentation of COVID-19 (Brodin, 2021). These inflammatory mediators include CCL5, CCL-11, chymase, IL-1 $\beta$ , IL-6, TGF $\beta$ , and PAF, mostly released from mast cells in response to environmental triggers including SARS-CoV-2 (Theoharides, 2020b; Motta Junior, et al., 2020). Moreover, mast cell activation in patients with COVID-19 was confirmed through serum elevation of the mast-cell-specific protease chymase (Tan, et al., 2021). A recent study reported that the SARS-CoV-2 spike protein could directly stimulate mast cells in ACE2 humanized mice and result in lung injury (Wu, et al., 2021), and it was proposed that the spike protein may be the key pathogenetic factor in Long COVID syndrome (Theoharides, 2022).

This case illustrates that mast cell activation may be associated with COVID-19 and an integrated treatment approach addressing mast cells and their proinflammatory mediators could be quite effective. Similar approaches may also be useful in managing patients at risk of anaphylaxis after COVID-19 vaccination (Gangemi, et al., 2021) as well as Long COVID (Theoharides, 2022).

#### Conflict of Interest

TCT is the Scientific Director of Algonot, LLC (Sarasota, FL) that develops flavonoid-containing dietary supplements. All other authors have no conflicts of interest to declare.

#### Funding

None.

## Ethical Approval

The patient has provided written permission to review her medical records and write this report.

## Author contributions

LG, the COVID Clinic physician, and CP, the Advanced Lung Disease and Transplant Clinic physician, were directly responsible for the care of this patient; they also reviewed and approved the manuscript. TCT was consulted, discussed the case, provided the integrative approach, searched the literature, and wrote the manuscript.

## Supplementary materials

Supplementary material associated with this article can be found, in the online version, at doi:[10.1016/j.ijid.2022.02.049](https://doi.org/10.1016/j.ijid.2022.02.049).

## References

- Afrin LB, Weinstock LB, Molderings GJ. Covid-19 hyperinflammation and post-Covid-19 illness may be rooted in mast cell activation syndrome. *Int J Infect Dis* 2020;100:327–32.
- Alevizos M, Karagkouni A, Vasiadi M, Sismanopoulos N, Makris M, Kalogeromitros D, et al. Rupatadine inhibits inflammatory mediator release from human LAD2 cultured mast cells stimulated by PAF. *Ann Allergy Asthma Immunol* 2013;111:524–7.
- Brodin P. Immune determinants of COVID-19 disease presentation and severity. *Nat Med* 2021;27:28–33.
- Demopoulos C, Antonopoulou S, Theoharides TC. COVID-19, microthromboses, inflammation, and platelet activating factor. *Biofactors* 2020;46:927–33.
- Di PF, Derosa G, Maffioli P, Bertuccioli A, Togni S, Riva A, et al. Possible Therapeutic Effects of Adjuvant Quercetin Supplementation Against Early-Stage COVID-19 Infection: A Prospective, Randomized, Controlled, and Open-Label Study. *Int J Gen Med* 2021;14:2359–66.
- Ehrenreich H, Weissenborn K, Begemann M, Busch M, Vieta E, Miskowiak KW. Erythropoietin as candidate for supportive treatment of severe COVID-19. *Mol Med* 2020;26:58.
- Freedberg DE, Conigliaro J, Wang TC, Tracey KJ, Callahan MV, Abrams JA. Famotidine Use Is Associated With Improved Clinical Outcomes in Hospitalized COVID-19 Patients: A Propensity Score Matched Retrospective Cohort Study. *Gastroenterology* 2020;159:1129–31.
- Gangemi S, Allegra A, Di GM. Management of patients at risk of anaphylaxis after COVID 19 vaccination. *J Biol Regul Homeost Agents* 2021;35:843–6.
- Karonova TL, Andreeva AT, Golovatuk KA, Bykova ES, Simanenkova AV, Vashukova MA, et al. Low 25(OH)D Level Is Associated with Severe Course and Poor Prognosis in COVID-19. *Nutrients* 2021;13:3021.
- Liu ZQ, Li XX, Qiu SQ, Yu Y, Li MG, Yang LT, et al. Vitamin D contributes to mast cell stabilization. *Allergy* 2017;72:1184–92.
- Motta Junior JDS, Miggiolaro AFRD, Nagashima S, de Paula CBV, Baena CP, Scharfstein J, et al. Mast Cells in Alveolar Septa of COVID-19 Patients: A Pathogenic Pathway That May Link Interstitial Edema to Immunothrombosis. *Front Immunol* 2020;11.
- Shadrack DM, Deogratias G, Kiruri LW, Onoka I, Vianney JM, Swai H, et al. Luteolin: a blocker of SARS-CoV-2 cell entry based on relaxed complex scheme, molecular dynamics simulation, and metadynamics. *J Mol Model* 2021;27:221.
- Shah PM, Boulos PB, Springall R, Vashisht R, Pearce FL. Effects of the H2-antagonists famotidine and nizatidine and the cytoprotectant misoprostol on human colonic and rat peritoneal mast cells. *Agents Actions* 1994;41 Spec No:C51–2.
- Tan J, Anderson DE, Rathore APS, O'Neill A, Mantri CK, Saron WAA, et al. Signatures of mast cell activation are associated with severe COVID-19. *medRxiv* 2021 05.31.21255594. doi:[10.1101/2021.05.31.21255594](https://doi.org/10.1101/2021.05.31.21255594).
- Theoharides TC. Vitamin D and Atopy. *Clin Ther* 2017;39:880–3.
- Theoharides TC. COVID-19, pulmonary mast cells, cytokine storms, and beneficial actions of luteolin. *Biofactors* 2020a;46:306–8.
- Theoharides TC. Potential Association of Mast Cells with COVID-19. *Ann Allergy Asthma Immunol* 2020b;126:217–18.
- Theoharides TC. Could SARS-CoV-2 Spike Protein Be Responsible for Long-COVID Syndrome? *Mol Neurobiol* 2022;13:1–12.
- Theoharides TC, Conti P. COVID-19 and Multisystem Inflammatory Syndrome, or is it Mast Cell Activation Syndrome? *J Biol Regul Homeost Agents* 2020;34:1633–6.
- Wang ZZ, Li K, Maskey AR, Huang W, Toutov AA, Yang N, et al. A small molecule compound berberine as an orally active therapeutic candidate against COVID-19 and SARS: A computational and mechanistic study. *FASEB J* 2021;35:e21360.
- Weinstock LB, Brook JB, Walters AS, Goris A, Afrin LB, Molderings GJ. Mast cell activation symptoms are prevalent in Long-COVID. *Int J Infect Dis* 2021;112:217–26.
- Wu ML, Liu FL, Sun J, Li X, He XY, Zheng HY, et al. SARS-CoV-2-triggered mast cell rapid degranulation induces alveolar epithelial inflammation and lung injury. *Signal Transduct Target Ther* 2021;6:428.
- Yip KH, Kolesnikoff N, Yu C, Hauschild N, Taing H, Biggs L, et al. Mechanisms of vitamin D(3) metabolite repression of IgE-dependent mast cell activation. *J Allergy Clin Immunol* 2014;133:1356–64 1364.
- Zhou Z, Ren L, Zhang L, Zhong J, Xiao Y, Jia Z, et al. Heightened Innate Immune Responses in the Respiratory Tract of COVID-19 Patients. *Cell Host Microbe* 2020;27:883–90.