



## Case Report

## Acute encephalopathy in a 6-year-old child with concurrent COVID-19 infection: a case report from Saudi Arabia



Ali Alsuehel Asseri<sup>1</sup>, Mohammed Assiri<sup>2</sup>, Mohammed Abdullah Alshehri<sup>1</sup>, Malak Asseri<sup>2</sup>, Abdelwahid Saeed Ali<sup>3</sup>, Nabil J. Awadalla<sup>4,5,\*</sup>

<sup>1</sup> Department of Pediatrics, King Khalid University, Abha 62529, Saudi Arabia

<sup>2</sup> Department of Pediatrics, Abha Maternity and Children Hospital, Abha 62521, Saudi Arabia

<sup>3</sup> Department of Microbiology and Clinical Parasitology, College of Medicine, King Khalid University, Abha 62529, Saudi Arabia

<sup>4</sup> Department of Family and Community Medicine, College of Medicine, King Khalid University, Abha 62529, Saudi Arabia

<sup>5</sup> Department of Community Medicine, Mansoura University, Mansoura 35516, Egypt

## ARTICLE INFO

## Article history:

Received 9 March 2022

Revised 23 July 2022

Accepted 16 August 2022

## Keywords:

COVID-19

Children

Encephalopathy

Status epilepticus

## ABSTRACT

COVID-19 is a global health crisis that has impacted the world with heavy economic and social losses. In the early days of the pandemic, pediatric COVID-19 was well-known for its low infectivity and mortality rates as well as its benign clinical outcomes. Herein, we report the case of a 6-year-old girl with COVID-19-associated encephalopathy without respiratory symptoms. To the best of our knowledge, this is the first child reported from Saudi Arabia with COVID-19-induced encephalopathy. A 6-year-old patient with COVID-19 was presented to the Abha Maternity and Child Hospital in southeastern Saudi Arabia. Routine clinical and laboratory examinations revealed normal findings. Despite the absence of COVID-19 respiratory manifestations, the patient manifested COVID-19-related encephalopathy. The patient responded well to pulse steroid, favipiravir, and symptomatic seizure therapies. The patient recovered completely without any neurologic morbidities. A COVID-19-related encephalopathy was observed for the first time in Saudi Arabia among pediatric patients. Clinicians should be alert to potential neurologic complications associated with COVID-19. It should be considered in the differential diagnosis of children presenting with acute encephalopathy, even in the absence of respiratory symptoms. To avoid long-term neurologic sequelae, prompt seizure and immunosuppressive therapies are essential.

© 2022 The Author(s). Published by Elsevier Ltd on behalf of International Society for Infectious Diseases.

This is an open access article under the CC BY-NC-ND license (<http://creativecommons.org/licenses/by-nc-nd/4.0/>)

## Introduction

Although the primary target of SARS-CoV-2 is the respiratory system, neurologic manifestations, including encephalopathy, have been reported in some patients (Akin *et al.*, 2021; Lin *et al.*, 2021; McAbee *et al.*, 2020; Singh *et al.*, 2022; Vraka *et al.*, 2021). The first case of meningoencephalitis associated with SARS-CoV-2 infection was reported in an adult patient in March 2020, with a positive specific SARS-CoV-2 RNA in the cerebrospinal fluid (CSF) (Poyiadji *et al.*, 2020). Since then, only a few case reports have described the association of COVID-19 with encephalopathy or encephalitis in children (Gaughan *et al.*, 2021; Vraka *et al.*, 2021). Herein, we

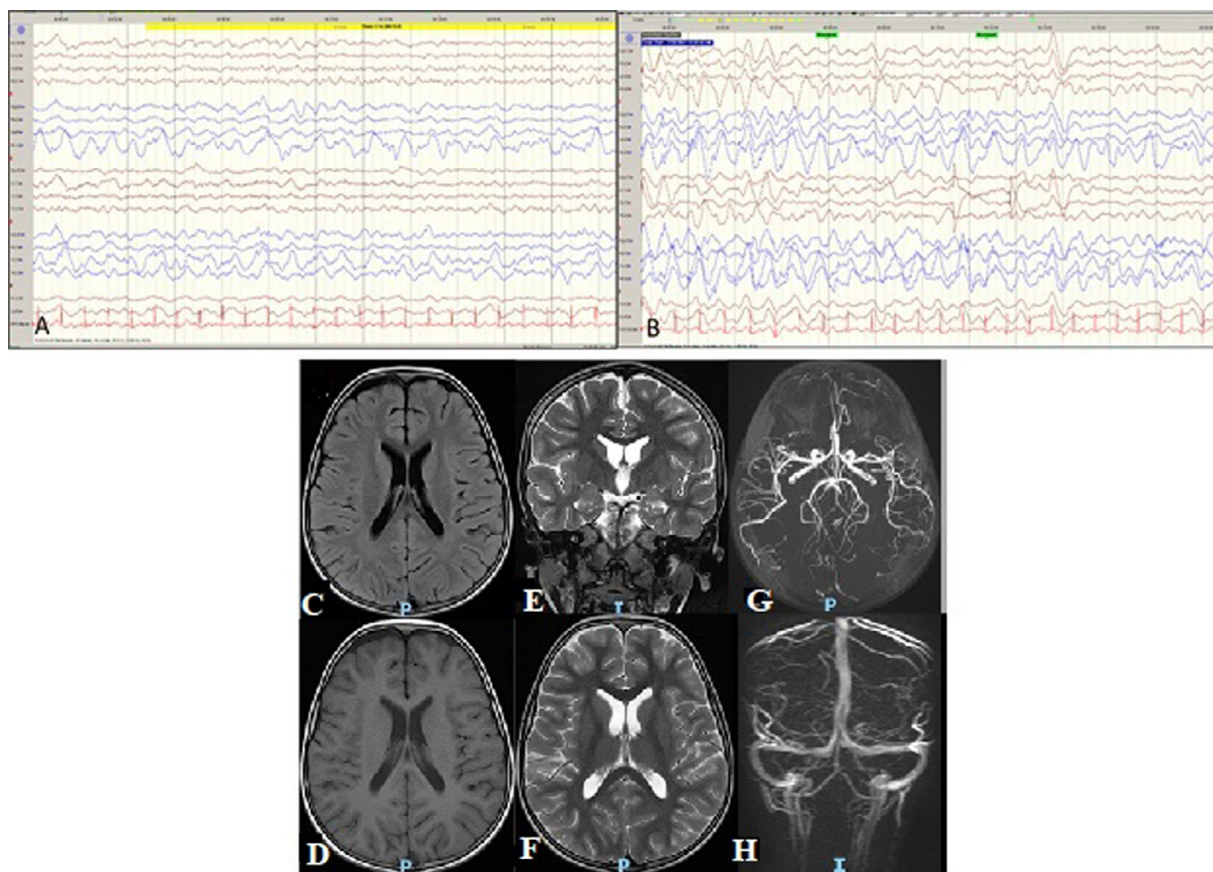
report the case of a 6-year-old girl with COVID-19-associated encephalopathy without respiratory symptoms. To the best of our knowledge, this is the first child reported from Saudi Arabia with COVID-19-induced encephalopathy.

## Case report

A previously healthy 6-year-old girl presented to a local hospital in the Asir region of Saudi Arabia during the current COVID-19 pandemic with frequent episodes of abnormal tonic movements of the upper limbs for 2 days. There was no history of fever or family history of epilepsy. The parents had a recent COVID-19 infection and were treated as outpatients. Initial examination revealed normal vital signs (oxygen saturation of 95% on room air) and physical examination, including a neurologic examination. Laboratory tests revealed a low white blood cell count ( $3.1 \times 10^3/\mu\text{l}$ ) and normal hemoglobin and platelet counts. CSF analysis showed normal pro-

\* Corresponding author: Dr. Nabil Joseph Awadalla, Department of Family and Community Medicine, College of Medicine, King Khalid University, Abha, Saudi Arabia. Telephone: +966533487152

E-mail address: [njgirgis@yahoo.co.uk](mailto:njgirgis@yahoo.co.uk) (N.J. Awadalla).



**Figure 1.** EEG and MRI of brain on day 4 of admission. (a) EEG showing generalized slow activities and (b) generalized slow activity superimposed with spikes involving the right hemisphere. MRI C (axial flair), D (axial T1 weighted), E (coronal T2 weighted), F (axial T2 weighted), G (Magnetic Resonance Angiography), and H (Magnetic Resonance Venography) show no evidence of acute infarction or intracranial hemorrhage. No space-occupying lesion. No abnormal focal parenchymal or meningeal enhancement. Normal appearance of the circle of Willis. No evidence of dual venous sinus thrombosis. EEG, Electroencephalography; MRI, Magnetic resonance imaging.

tein and glucose levels and an absence of white blood cell. CSF bacterial cultures and herpes simplex virus 1 and 2 tests were negative. Complete metabolic panels were within the normal ranges. An initial chest radiograph revealed normal findings. A real-time reverse transcription-polymerase chain reaction test for the detection of COVID-19 was performed, and the patient was started on intravenous ceftriaxone, vancomycin, acyclovir, and oral levetiracetam, with an impression of acute meningoencephalitis. There was no improvement in seizure frequency with this regimen, and the patient developed auditory hallucinations. The patient was then transferred to the Abha Maternity and Child Hospital for further management.

The patient's vital signs were normal upon admission to the Abha Maternity and Child Hospital. Neurologic examination revealed normal tone, power, and reflexes. The patient reported frequent episodes of auditory hallucinations. Immediately after admission, she developed status epilepticus and persistent hallucinations and was admitted to the pediatric intensive care unit with a diagnosis of status epilepticus and suspected COVID-19-related encephalopathy. White blood cell, neutrophil-to-lymphocyte ratio, C-reactive protein, and procalcitonin levels were within the normal limits. D-dimer level was elevated to 8.09 mg/l upon admission (reference value, <0.73 mg/l). Nasopharyngeal SARS-CoV-2 reverse transcription-polymerase chain reaction results have been reported to be positive. The myelin oligodendrocyte glycoprotein antibody, anti-N-methyl-D-aspartate receptor, and voltage-gated potassium channel antibodies were negative. Tandem mass

spectrometry was performed for common Saudi metabolic disorders (Mohamed et al., 2020), and the results were negative. Electroencephalography (EEG) revealed generalized slow activity superimposed with epileptic spikes in the right hemisphere (Figures 1a and 1b).

Based on the clinical findings, EEG results, negative CSF viral panel, and bacterial cultures, the impression was COVID-19-induced encephalopathy. The patient was treated with methylprednisolone pulse therapy (30 mg/kg/day) for 3 days and favipiravir for 7 days. Midazolam infusion with loading doses of phenytoin and phenobarbitone was initiated according to the Saudi Arabian clinical practice guidelines for treating children with convulsive status epilepticus (Bashiri et al., 2017). In addition, she was given two doses of intravenous immunoglobulin (1 g/kg for 2 days). Levetiracetam was discontinued and replaced with topiramate. Valproate was added on the second day because of persistent convulsive status epilepticus. On the third day of admission, the patient had a normal central nervous system (CNS) examination, with no seizures or hallucinations. She was then transferred to the general pediatric ward to complete the course of therapy. Brain magnetic resonance imaging on the fourth day of admission revealed normal findings (Figures 1C–H). After 7 days of hospitalization, the patient was sent home on oral prednisolone (1 mg/kg/day), topiramate, and valproate. After 3 weeks of hospitalization, the patient was seen in the pediatric clinic; the seizure was well controlled, and she had a normal examination. The systemic steroid was weaned off for over 3 weeks, and the antiepileptics were continued.

## Discussion

Acute pediatric encephalopathy is a clinical syndrome characterized by a reduced level of consciousness due to various pathological disorders, such as infectious diseases, metabolic disorders, and drugs (Thompson et al., 2012). The clinical presentations are age-dependent, including altered consciousness, regression of developmental milestones, and personality changes (e.g., hallucinations). In addition, encephalopathy can lead to seizures, ataxia, or focal motor weakness (Davies et al., 2012; Lim et al., 2020).

Our patient had acute encephalopathy and convulsive status epilepticus, with concurrent COVID-19 infection, even in the absence of respiratory symptoms. In addition, the patient developed auditory hallucinations with a very disturbing level of consciousness. EEG reveals slow activity superimposed with epileptic spikes. Therefore, the patient required midazolam infusion and loading doses of phenytoin, phenobarbitone, topiramate, and valproate to control her seizures. In addition, the patient was administered pulse steroids, immunoglobulins, and favipiravir. The constellation of the clinical signs and symptoms, absence of CSF inflammatory findings, EEG findings, and normal magnetic resonance imaging suggested that our patient had encephalopathy.

Besides the well-known respiratory manifestations, SARS-CoV-2 infection has also been linked to neurologic complications in patients of all ages (Azizi and Azizi, 2020; Singh et al., 2022); however, the pathogenesis of COVID-19, associated with neurologic disease remains unclear (Carod-Artal, 2020). Recent research has controversial results about the neurotropic properties of the SARS-CoV-2 (Aschman et al., 2022; Lin et al., 2021). Moreover, several theories have been suggested, including direct and indirect pathways induced by the virus. The direct neuroinvasive effect of the virus could be explained by its retrograde movement to the CNS through the olfactory or peripheral lung nerves or by hematogenous migration through CNS endothelial cells that express angiotensin-converting enzyme 2 receptors (Azizi and Azizi, 2020). In addition, the leakage of inflammatory mediators through the permeable blood-brain barrier can serve as a possible means to convey the virus to the CNS as an indirect effect. These findings suggest that direct brain infection may be possible given the concurrent COVID-19 infection and absence of other systemic symptoms. Further studies are required to confirm this hypothesis. To exclude other causes of encephalopathy and seizures, our patient underwent extensive workup, including infectious etiologies, metabolic disorders, autoimmune encephalitis, and vascular anomalies, which revealed negative results.

Several neurologic involvements have previously been reported in patients with COVID-19 infection, including headaches, dizziness, and anosmia (Poyiadji et al., 2020). In addition, severe life-threatening complications have been reported, such as encephalopathy, encephalitis, necrotizing hemorrhagic encephalopathy, epileptic seizures, and Guillain-Barré syndrome. Although most of these severe manifestations have been reported in adult patients, few pediatric patients have such complications (Akin et al., 2021; Gaughan et al., 2021; Vraka et al., 2021). Based on a recently published meta-analysis, the authors found that in patients with COVID-19-induced encephalopathy, age 70–79 years, low admission lymphocyte counts, and use of corticosteroid and anticoagulants are considered poor prognostic factors (Singh et al., 2022). On the other hand, data about the pediatric COVID-19-induced encephalopathy are scarce, and most of the available data are based on case reports and few case series (Gaughan et al., 2021; McAbee et al., 2020). In COVID-19-induced encephalopathy, EEG abnormalities are prevalent, with diffuse slow-wave background activity and occasionally epileptic events being the most common results (Vraka et al., 2021). Our patient had a slow activity, with frequent spikes and sharp waves, mainly involving the right hemisphere. A

review concluded that generalized slowing, focal slowing, epileptiform discharges with seizures, and status epilepticus were the most commonly reported EEG abnormalities among patients with COVID-19 with neurologic involvement (Vellieux et al., 2020). However, further studies are needed to describe the exact phenotypical changes, EEG changes, and biochemical characteristics of pediatric CNS COVID-19.

The treatment team used the best available evidence for managing pediatric COVID-19-induced CNS involvement. The patient initially received broad-spectrum antibiotics and antiviral therapy, in addition to antiepileptic therapies. After ruling out common pathogens that could cause meningoencephalitis, steroids and intravenous immunoglobulin were started under close intensive care unit monitoring. These interventions are in agreement with previously reported therapies (Gaughan et al., 2021).

In conclusion, clinicians should be alert to neurologic complications associated with COVID-19. It should be considered in the differential diagnosis of children presenting with acute encephalopathy, even in the absence of respiratory symptoms. Prompt seizures and immunosuppressive therapies are essential to avoid long-term neurologic sequelae.

## Funding source

This research did not receive any specific grant from funding agencies in the public, commercial, or not-for-profit sectors.

## Ethical approval statement

Written informed consent was obtained from the patient's family before the creation of this report.

## Author contributions

None

## Declaration of competing interest

The authors have no competing interests to declare.

## Supplementary materials

Supplementary material associated with this article can be found, in the online version, at doi:[10.1016/j.ijid.2022.08.013](https://doi.org/10.1016/j.ijid.2022.08.013).

## References

- Akin ME, Çitak-Kurt ANÇ, Bayhan Gİ, Ezgü ZD, Bulut SŞ. Mild encephalopathy with reversible extensive white matter lesions in a child with acute adenoviral infection and a literature review. *Turk J Pediatr* 2021;63:516–21.
- Aschman T, Mothes R, Heppner FL, Radbruch H. What SARS-CoV-2 does to our brains. *Immunity* 2022;55:1159–72.
- Azizi SA, Azizi SA. Neurological injuries in COVID-19 patients: direct viral invasion or a bystander injury after infection of epithelial/endothelial cells. *J Neurovirol* 2020;26:631–41.
- Bashiri FA, Hamad MH, Amer YS, Abouelkheir MM, Mohamed S, Kentab AY, et al. Management of convulsive status epilepticus in children: an adapted clinical practice guideline for pediatricians in Saudi Arabia. *Neurosciences (Riyadh)* 2017;22:146–55.
- Carod-Artal FJ. Neurological complications of coronavirus and COVID-19. *Rev Neurol* 2020;70:311–22.
- Davies E, Connolly DJ, Mordekar SR. Encephalopathy in children: an approach to assessment and management. *Arch Dis Child* 2012;97:452–8.
- Gaughan M, Connolly S, O'Riordan S, Tubridy N, McGuigan C, Kinsella JA. Pediatric parainfectious encephalitis associated with COVID-19. *Neurology* 2021;96:541–4.
- Lim YXJ, Kwek SY, How CH, Chan WSD. A clinical approach to encephalopathy in children. *Singapore Med J* 2020;61:626–32.
- Lin JE, Asfour A, Sewell TB, Hooe B, Pryce P, Earley C, et al. Neurological issues in children with COVID-19. *Neurosci Lett* 2021;743.
- McAbee GN, Brosgol Y, Pavlakis S, Agha R, Gaffoor M. Encephalitis associated with COVID-19 infection in an 11-year-old child. *Pediatr Neurol* 2020;109:94.

- Mohamed S, Elsheikh W, Al-Aqeel AI, Alhashem AM, Alodaib A, Alahaideb L, et al. Incidence of newborn screening disorders among 56632 infants in Central Saudi Arabia. A 6-year study. *Saudi Med J* 2020;41:703–8.
- Poyiadji N, Shahin G, Noujaim D, Stone M, Patel S, Griffith B. COVID-19-associated acute hemorrhagic necrotizing encephalopathy: imaging features. *Radiology* 2020;296:E119–20.
- Singh B, Lant S, Cividini S, Cattrall JWS, Goodwin LC, Benjamin L, et al. Prognostic indicators and outcomes of hospitalised COVID-19 patients with neurological disease: an individual patient data meta-analysis. *PLoS One* 2022;17.
- Thompson C, Kneen R, Riordan A, Kelly D, Pollard AJ. Encephalitis in children. *Arch Dis Child* 2012;97:150–61.
- Vellieux G, Sonnevile R, Vledouts S, Jaquet P, Rouvel-Tallec A, d'Ortho MP. COVID-19-associated neurological manifestations: an emerging electroencephalographic literature. *Front Physiol* 2020;11.
- Vraka K, Ram D, West S, Chia WYE, Kurup P, Subramanian G, et al. Two paediatric patients with encephalopathy and concurrent COVID-19 infection: two sides of the same coin? *Case Rep Neurol Med* 2021;2021.