



Case Report

The first case of meningitis associated with SARS-CoV-2 BA.2 variant infection with persistent viremia



Alessandra D'Abramo¹, Serena Vita^{1,*}, Francesca Colavita¹, Eleonora Cimini¹, Shalom Haggiag², Gaetano Maffongelli¹, Maria Beatrice Valli¹, Nazario Bevilacqua¹, Angela Corpolongo¹, Maria Letizia Giancola¹, Fabrizio Maggi¹, Chiara Agrati¹, Emanuele Nicastrì¹

¹ National Institute of Infectious Diseases Lazzaro Spallanzani, Institute of Hospitalization and Scientific Care, Rome, Italy

² Department of Neurology, San Camillo-Forlanini, Rome, Italy

ARTICLE INFO

Article history:

Received 5 August 2022

Revised 30 August 2022

Accepted 8 September 2022

Keywords:

COVID-19

Meningitis

Omicron

Blood barrier damage

ABSTRACT

Severe neurological disorders and vascular events during COVID-19 have been described. Here, we describe the first case of a female patient infected with the SARS-CoV-2 BA.2 Omicron variant of concern with meningitis with newly diagnosed central demyelinating disease.

© 2022 Published by Elsevier Ltd on behalf of International Society for Infectious Diseases.

This is an open access article under the CC BY-NC-ND license

(<http://creativecommons.org/licenses/by-nc-nd/4.0/>)

Introduction

Neurological symptoms of COVID-19 are highly frequent and disabling (Wan *et al.*, 2021). Severe neurological disorders such as encephalitis, meningitis, Guillain-Barré syndrome, and vascular events have been described in anecdotal reports or in case series. Here, we describe the first case of a female patient infected with the SARS-CoV-2 BA.2 Omicron variant of concern (VoC) meningitis with newly diagnosed central demyelinating disease.

Materials and methods

Clinical specimens, including nasopharyngeal swabs (NPSs), cerebral spinal fluid (CSF), and blood specimens, were collected for SARS-CoV-2 diagnostic testing in accordance with World Health Organization guidelines. Clinical information was obtained from hospital data records, including demographic and medical history, underlying comorbidities, symptoms, signs, laboratory findings, chest computed tomography scans, cerebral magnetic resonance imaging, treatment regimens, and clinical outcomes. A commercial real-time reverse transcription-polymerase chain reaction

was used to detect the presence of SARS-CoV-2 RNA in NPS, CSF, and blood. The characterization of viral VoCs was performed using sanger sequencing of the spike (S) gene. Inflammatory cytokines (interleukins [ILs]: IL-1 β , IL-6, and IL-8; tumor necrosis factor [TNF]- α) were detected in liquor and plasma samples by enzyme-linked immunosorbent assay; two-step automated chemiluminescence microparticle assays were performed to measure antinucleoprotein immunoglobulin (Ig) G and anti-S/receptor binding domain IgG in serum, whereas anti-SARS-CoV-2 antibodies (IgG, IgM, and IgA) in CSF and in matched serum samples were evaluated by home-made indirect immunofluorescence assays, as described elsewhere (Colavita *et al.*, 2020).

Case presentation

On March 12, 2022, a female patient aged 47 years was infected with SARS-CoV-2 and was admitted to the Lazzaro Spallanzani National Institute for Infectious Diseases in Rome, Italy. The patient did not receive the SARS-CoV-2 vaccination. On March 2, the patient was diagnosed with left optic neuritis and underwent high-dose intravenous corticosteroid therapy. One week later, she complained of back pain, tingling and numbness in lower limbs, and gait instability. On March 11, for the worsening neurological symptoms, she presented to the emergency department. The patient's NPS was positive for SARS-CoV-2. She underwent a full body

* Corresponding author: Serena Vita, via portuense 240, Via Portuense 292, 00149 Rome Italy.

E-mail address: serena.vita@inmi.it (S. Vita).

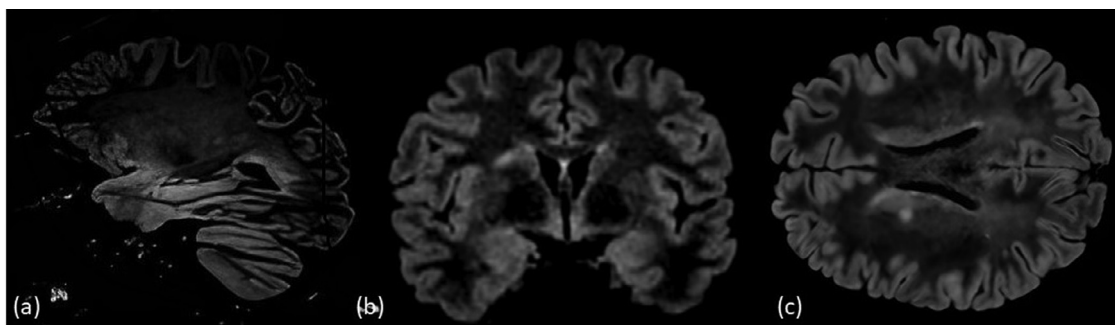


Figure 1. The T2-weighted images shows two hyperintense lesions in the right corona radiata (a, b) and left trigone of the lateral ventricle (c).

computed tomography scan, the result of which was normal with no lung involvement. A magnetic resonance imaging of the brain and spinal cord showed the presence of a 7-mm non-enhancing T2-hyperintense lesion in the right capsular nucleus region. Other sub-centimetric lesions were observed in the white matter of the left superior parietal gyrus, the right angular gyrus, and the inferior frontal gyrus (Figure 1). A single lesion with slight enhancement at the cone level was observed, consistent with the clinical presentation. A lumbar puncture was performed and CSF analysis revealed 122 cells/mm³ (75% lymphocytes), and an increased level of protein (183 mg/dl), with normal glucose. Empiric treatment with intravenous (IV) acyclovir (10 mg/kg every 8 hours) and ampicillin (2 grams every 6 hours) was started. Simultaneous testing by polymerase chain reaction on CSF (Film Array by Biomerieux) was negative for neurotropic pathogens as gram and fungal stains and bacterial cultures. On March 12, she was referred to the Lazzaro Spallanzani National Institute for Infectious Diseases isolation unit. Considering the patient's neurological symptoms and the previous treatment with high-dose steroids, a SARS-CoV-2 molecular test on the patient's CSF was requested, which resulted positive (cycle threshold [CT]: 39). Moreover, SARS-CoV-2 RNA was detected in plasma (CT: 30.6). Viral S gene sequencing on plasma and NPS resulted in an Omicron BA.2 VoC. Common serology against anti-S/receptor binding domain and antinucleoprotein were all negative, as in the case of anti-SARS-CoV-2 IgG, IgM, and IgA serology in plasma and CSF. Results of inflammatory cytokines showed a higher level of IL-8 in CSF than in the plasma sample (1722 pg/ml vs 4.57 pg/ml, respectively), whereas no differences were observed in IL-1 β , IL-6, and TNF- α production in the CSF and plasma (IL-1 β : 0.3 vs 0 pg/ml; IL-6: 7.3 vs 3.5 pg/ml; TNF- α : 1.5 vs 4.2 pg/ml, respectively) (Table 1). On March 15, SARS-CoV-2 RNA was still detected in the patient's plasma sample (CT: 34). Protein parameters in CSF and serum (IgG, albumin, albumin CSF/serum ratio, IgG index, IgG/CSF albumin) suggested a blood-brain barrier (BBB) damage, and the isoelectric focusing revealed a single supernumerary band. Peripheral T and B lymphocyte count and natural killer cells were within normal ranges. Antibodies against aquaporin-4, myelin oligodendrocyte glycoprotein, and myeloperoxidase and

proteinase 3 antineutrophil cytoplasmic extractable nuclear antigens were all negative. After admission, the patient was immediately started on a 5-day course of IV remdesivir, IV single dose of sotrovimab, and oral steroids (prednisolone 1 mg/kg for 5 days, followed by a 5-day course of tapering steroid dose). A clear and progressive improvement of the neurological symptoms was observed. On March 21, she was discharged and referred as an outpatient to the multiple sclerosis center. On March 28, the patient's NPS for SARS-CoV-2 was negative.

Discussion

Neurological syndromes due to SARS-CoV-2 infection have been rarely reported (Wan et al., 2021). The first case of meningitis associated with SARS-CoV-2 detection was described in a 24-year-old man in March 2020, with a positive real-time reverse transcription-polymerase chain reaction for SARS-CoV-2 in the patient's CSF sample (Moriguchi et al., 2020). A recent review described 11 cases of SARS-CoV-2 central nervous system (CNS) involvement from the start of the pandemic until September 2021, but only three cases tested positive for SARS-CoV-2 in the CSF. All reported cases were identified during Alpha and Delta SARS-CoV-2 variants circulation, but no sequencing data were given (da Silva et al., 2022). Here, we describe the first case of meningitis in a young adult woman with a recent diagnosis of CNS demyelinating disease associated with SARS-CoV-2 BA.2 Omicron VoC infection. Higher transmissibility, decreased vaccination effectiveness, and an increased risk of reinfection are all characteristics related to the new Omicron variant of SARS-CoV-2. The Omicron variant is less dependent on the viral entry mediated by transmembrane protein serine protease 2 and replicates well in the upper respiratory tract but poorly in the lower respiratory tract (Dhawan and Priyanka, 2022; Shuai et al., 2022). There are several underlying conditions associated with greater severity of COVID-19; however, no specific risk factors have been described for brain involvement by SARS-CoV-2 infection. The neurological findings related to SARS-CoV-2 infection and the pathogenesis of CNS diseases are not completely understood. In our case, immunosuppression induced by recent high-dose steroid therapy contributed to the presence and persistence of plasma viremia in the absence of any specific serology. The blood barrier damage sustained by the recent demyelinating disease might contribute to the low-level viral detection in the CNS, with high levels of inflammation markers, as supported by the relevant increase of IL-8 levels. SARS-CoV-2 enters into cells through the angiotensin-converting enzyme 2 (ACE2) receptors and transmembrane protein serine protease 2 serine protease, which are highly expressed in the lung and at lower suppressed levels in the brain (Hamming et al., 2004; Hoffmann et al., 2020). Moreover, SARS-CoV-2 could invade cells through the alternative accessory receptors including neuropilin-1, basigin, cathepsin L, and furin proteins. All these proteins are highly expressed in the human

Table 1
Patient's laboratory findings.

	Plasma	Cerebral spinal fluid
IL-8 (pg/ml)	4.57	1722
IL-1 β (pg/ml)	0	0.3
IL-6 (pg/ml)	3.5	7.3
TNF- α (pg/ml)	4.2	1.5
SARS-CoV-2 RNA CT March 12	30.6	39
March 15	34	NA
March 28	negative	NA

CT, cycle threshold; IL, interleukin; NA: not available; TNF, tumor necrosis factor.

brain (Cantuti-Castelvetri *et al.*, 2020; Chen *et al.*, 2020; Coutard *et al.*, 2020; Huang *et al.*, 2006). Different mechanisms of SARS-CoV-2 neuroinvasion were described: through the olfactory nerve through the angiotensin-converting enzyme 2 receptor expressed on horizontal basal cells (Wan *et al.*, 2021) and the hematogenous way through the infection of vascular endothelial cells to cross the BBB and the induction of inflammatory responses to disrupt the BBB (Kempuraj *et al.*, 2020; Varga *et al.*, 2020). In our case, early combined antiviral therapy, including remdesivir and sotrovimab, was successfully administered immediately after hospitalization, considering that remdesivir use is associated with a good brain diffusion until 25% of the paired plasma therapeutic level (Tempestilli *et al.*, 2020). Although no data are available, we assumed there was a good sotrovimab CSF penetration of the BBB. In the setting of patients who are immunocompromised who are at a higher risk for persistent plasma viremia with no specific SARS-CoV-2 serology, detection of SARS-CoV-2 in the CNS during a likely BBB injury should be suspected even in the absence of lung involvement.

Funding

This work was supported by Line1 Ricerca Corrente “Studio dei patogeni ad alto impatto sociale: emergenti, da importazione, multiresistenti, negletti”, funded by the Italian Ministry of Health.

Ethical approval

Ethical committee approval was not required due to the observational nature of the study. Patient written informed consent for publication was collected. The data were obtained from medical records and reviewed by a trained team of physicians.

Authors' contributions

AD, SV, EN conceived the study and drafted the first version of the manuscript. SH, MLG, AC, NB, GM followed the patients during the diagnostic and therapeutic path. FC, MBV, FM, EC, GA performed virological and immunological experiments. CA, FM, EN reviewed and supervised the final version of the manuscript. All authors gave their final approval of the version to be submitted.

Declaration of Competing Interest

The authors have no competing interests to declare.

Acknowledgments

The authors would like to thank the Spallanzani COVID-19 Case Investigation Team: Laura Scorzolini, Tommaso Ascoli Bartoli, Andrea Mariano, Ambrogio Curtolo, Francesca Faraglia, Virginia Tomassi, Silvia Rosati, Stefania Notari, Lavinia Fabeni and Silvia Meschi.

Supplementary materials

Supplementary material associated with this article can be found, in the online version, at doi:10.1016/j.ijid.2022.09.011.

References

- Cantuti-Castelvetri L, Ojha R, Pedro LD, Djannatian M, Franz J, Kuivanen S, van der Meer F, Kallio K, Kaya T, Anastasina M, Smura T, Levanov L, Szirovicza L, Tobi A, Kallio-Kokko H, Österlund P, Joensuu M, Meunier FA, Butcher SJ, Winkler MS, Mollenhauer B, Helenius A, Gokce O, Teesalu T, Hepojoki J, Vapalahti O, Stadelmann C, Balistreri G, Simons M. Neuropilin-1 facilitates SARS-CoV-2 cell entry and infectivity. *Science* 2020;370:856–60.
- Chen T, Wu D, Chen H, Yan W, Yang D, Chen G, Ma K, Xu D, Yu H, Wang H, Wang T, Guo W, Chen J, Ding C, Zhang X, Huang J, Han M, Li S, Luo X, Zhao J, Ning Q. Clinical characteristics of 113 deceased patients with coronavirus disease 2019: retrospective study. *BMJ* 2020;368:m1091.
- Colavita F, Lapa D, Carletti F, Lalle E, Messina F, Rueca M, Matusali G, Meschi S, Bordini L, Marsella P, Nicastrì E, Marchioni L, Mariano A, Scorzolini L, Bartoli TA, Di Caro A, Ippolito G, Capobianchi MR, Castilletti C. INMI COVID-19 Laboratory Team and INMI COVID-19 Study Group. Virological characterization of the first 2 COVID-19 patients diagnosed in Italy: phylogenetic analysis, virus shedding profile from different body sites, and antibody response kinetics. *Open Forum Infect Dis* 2020;7:ofaa403.
- Coutard B, Valle C, de Lamballerie X, Canard B, Seidah NG, Decroly E. The spike glycoprotein of the new coronavirus 2019-nCoV contains a furin-like cleavage site absent in CoV of the same clade. *Antiviral Res* 2020;176.
- Dhawan M, Priyanka Choudhary OP. Emergence of Omicron sub-variant BA.2: is it a matter of concern amid the COVID-19 pandemic? *Int J Surg* 2022;99.
- Hamming I, Timens W, Bulthuis ML, Lely AT, Navis GJ, van Goor H. Tissue distribution of ACE2 protein, the functional receptor for SARS coronavirus. A first step in understanding SARS pathogenesis. *J Pathol* 2004;203:631–7.
- Hoffmann M, Kleine-Weber H, Schroeder S, Krüger N, Herrler T, Erichsen S, Schiergens TS, Herrler G, Wu NH, Nitsche A, Müller MA, Drosten C, Pöhlmann S. SARS-CoV-2 cell entry depends on ACE2 and TMPRSS2 and is blocked by a clinically proven protease inhibitor. *Cell* 2020;181:271–280.e8.
- Huang IC, Bosch BJ, Li F, Li W, Lee KH, Ghiran S, Vasilieva N, Dermody TS, Harrison SC, Dormitzer PR, Farzan M, Rottier PJM, Choe H. SARS coronavirus, but not human coronavirus NL63, utilizes cathepsin L to infect ACE2-expressing cells. *J Biol Chem*. Amsterdam: Elsevier BV 2006;281:3198–203.
- Kempuraj D, Selvakumar GP, Ahmed ME, Raikwar SP, Thangavel R, Khan A, Zaheer SA, Iyer SS, Burton C, James D, Zaheer A. COVID-19, mast cells, cytokine storm, psychological stress, and neuroinflammation. *Neuroscientist* 2020;26:402–14.
- Moriguchi T, Harii N, Goto J, Harada D, Sugawara H, Takamino J, Ueno M, Sakata H, Kondo K, Myose N, Nakao A, Takeda M, Haro H, Inoue O, Suzuki-Inoue K, Kubokawa K, Ogihara S, Sasaki T, Kinouchi H, Kojin H, Ito M, Onishi H, Shimizu T, Sasaki Y, Enomoto N, Ishihara H, Furuya S, Yamamoto T, Shimada S. A first case of meningitis/encephalitis associated with SARS-Coronavirus-2. *Int J Infect Dis* 2020;94:55–8.
- Shuai H, Chan JFW, Hu B, Chai Y, Yuen TTT, Yin F, Huang X, Yoon C, Hu JC, Liu H, Shi J, Liu Y, Zhu T, Zhang J, Hou Y, Wang Y, Lu L, Cai JP, Zhang AJ, Zhou J, Yuan S, Brindley MA, Zhang BZ, Huang JD, To KKW, Yuen KY, Chu H. Attenuated replication and pathogenicity of SARS-CoV-2 B.1.1.529 Omicron. *Nature* 2022;603:693–9.
- da Silva FJC, Farias LABG, de Holanda PEL, Nunes FR, Miyajima F, Damasceno LS. COVID-19-associated meningoencephalitis in a Brazilian patient: case report and literature review. *Rev Inst Med trop S Paulo* 2022;64:e14.
- Tempestilli M, Caputi P, Avataneo V, Notari S, Forini O, Scorzolini L, Marchioni L, Bartoli TA, Castilletti C, Lalle E, Capobianchi MR, Nicastrì E, D'Avolio A, Ippolito G, Agrati C. COVID 19 INMI Study Group. Pharmacokinetics of remdesivir and GS-441524 in two critically ill patients who recovered from COVID-19. *J Antimicrob Chemother* 2020;75:2977–80.
- Varga Z, Flammer AJ, Steiger P, Haberecker M, Andermatt R, Zinkernagel AS, Mehra MR, Schuepbach RA, Ruschitzka F, Moch H. Endothelial cell infection and endotheliitis in COVID-19. *Lancet* 2020;395:1417–18.
- Wan D, Du T, Hong W, Chen L, Que H, Lu S, Peng X. Neurological complications and infection mechanism of SARS-CoV-2. *Signal Transduct Target Ther* 2021;6:406.